Interpretation of chest x-ray & Pathology of lung

Rosy Perveen
Associate Professor (CC) & Head
Dept. of Radiology & Imaging
WMCH.

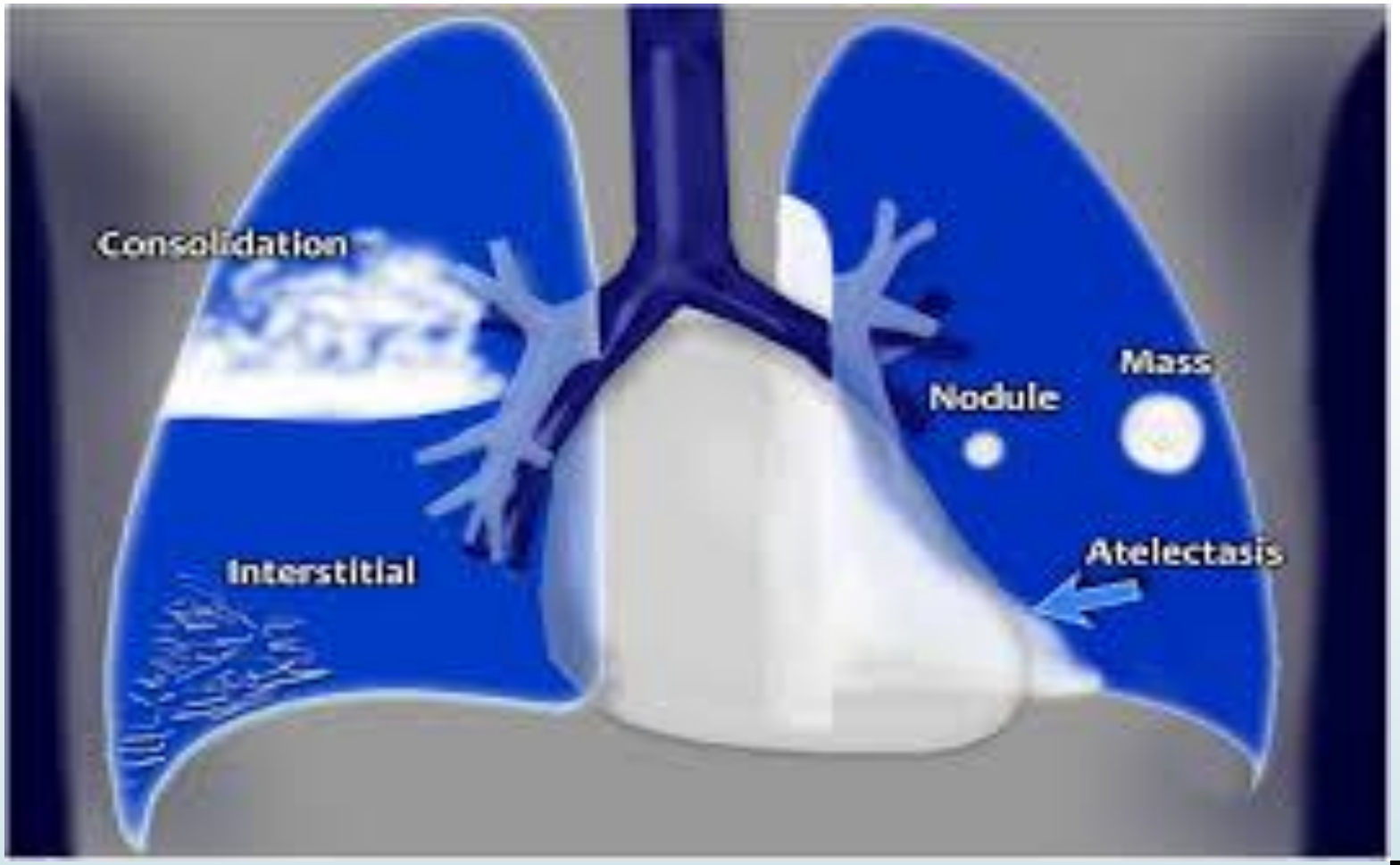
Consolidation
Mass
Nodule
Atelectasis
Interstitial

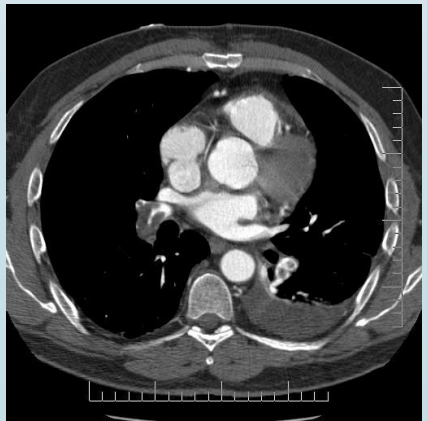


L

IMAGING MODALITIES

1. Plain chest Radiograph
2. Fluoroscopy
3. Computerized tomography
4. Radionuclide lung scan
5. MRI
6. Ultrasound
7. Pulmonary angiography

Plain chest radiograph

- Diagnostic in 80% cases
- Standard views
  1. Postero-anterior(P/A)
  2. Lateral (right/left)
- Additional views
  1. Oblique view(ribs)
  2. Apical, lordotic view
  3. Expiration view
  4. Decubitus view

Computed Tomography

- Numerous protocols/techniques depending on clinical history
- Helical/spiral versus high resolution
- Contrast
  - Renal failure
  - Allergy

Computed Tomography

- Role of CT
  - Main further investigation for most CXR abnormality (eg nodule/mass) or to exclude disease with normal CXR
  - Main investigation for certain scenarios (PE, dissection, trauma)

MRI

- Multiple planes
- No radiation
- Common Indication
  - Pancoast tumour
  - Brachial plexus
  - Cardiac
  - Vascular (aorta)
- Usually targeted examination (unlike CT)

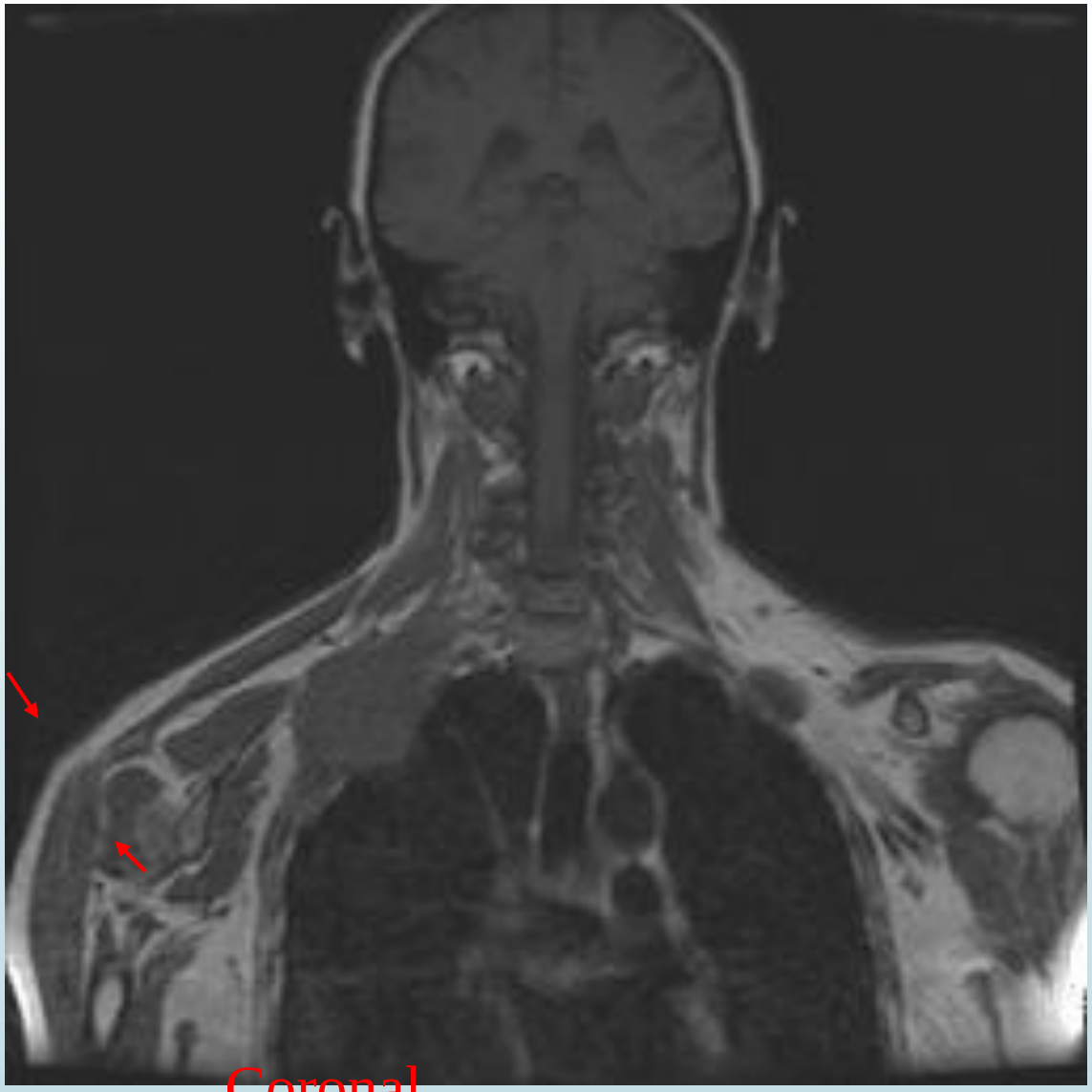

Nuclear Medicine

- Variety of tests: functional rather than anatomic
- V/Q specific to chest imaging
- Others: bone scan, gallium etc.

Ultrasound

- Limited use in thorax (non cardiac) due to air in lungs
- Assess pleural effusions
- Can be used in diagnosing consolidation too
- Mainly used for procedures

Chest Radiographs

- PA (posterior to anterior) and Lateral (left)
  - Minimizes magnification of heart (heart closest to film)
- Portable (nearly always AP)
  - Supine or Erect
- Specialized Views
  - Lordotic
  - Lateral decubitus (for effusions, pneumothorax)

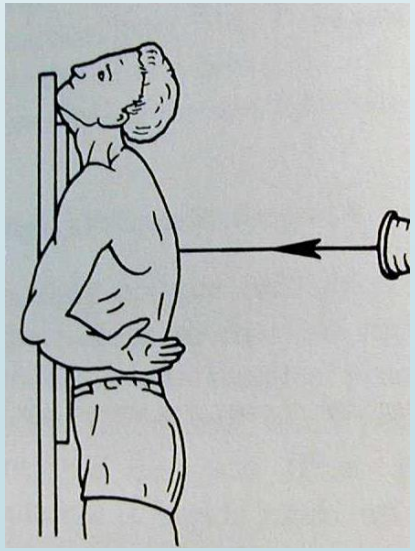

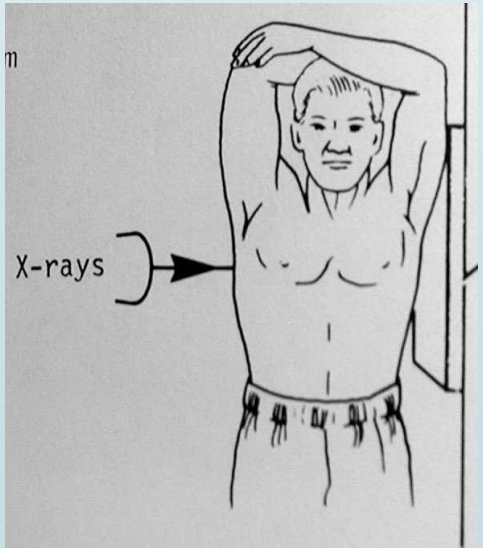

Five Radiographic Opacities

Air Fat Soft tissue Bone Metal

least opaque	to	most opaque
most lucent	to	least lucent
Black	to	White

Densities

The big two densities are:

(1) WHITE - Bone
(2) BLACK - Air

The others are:

(3) DARK GREY- Fat
(4) GREY- Soft tissue/water

And if anything Man-made is on the film, it is:

(5) BRIGHT WHITE - Man-made

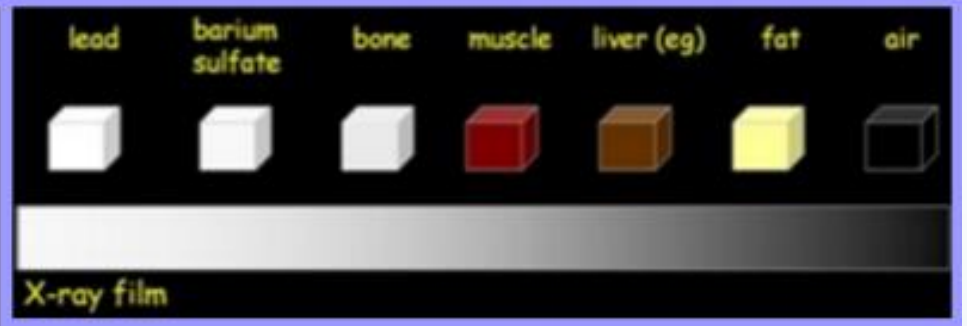

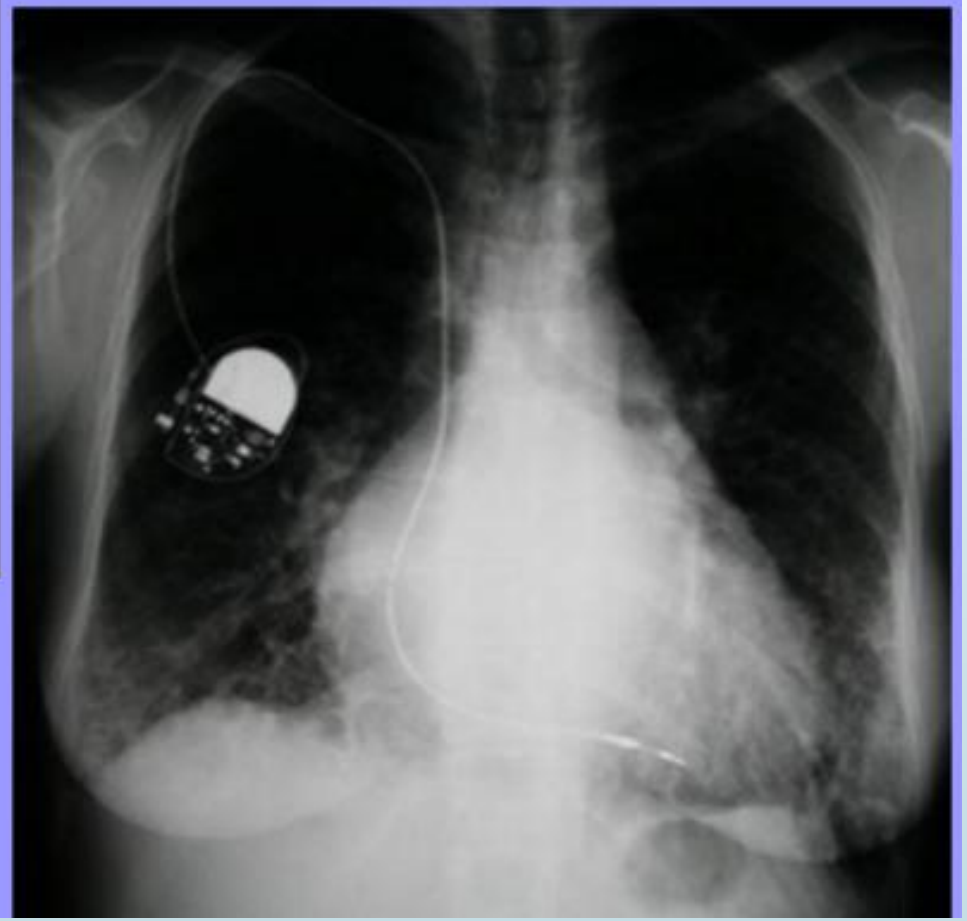

Anatomy in a CXR

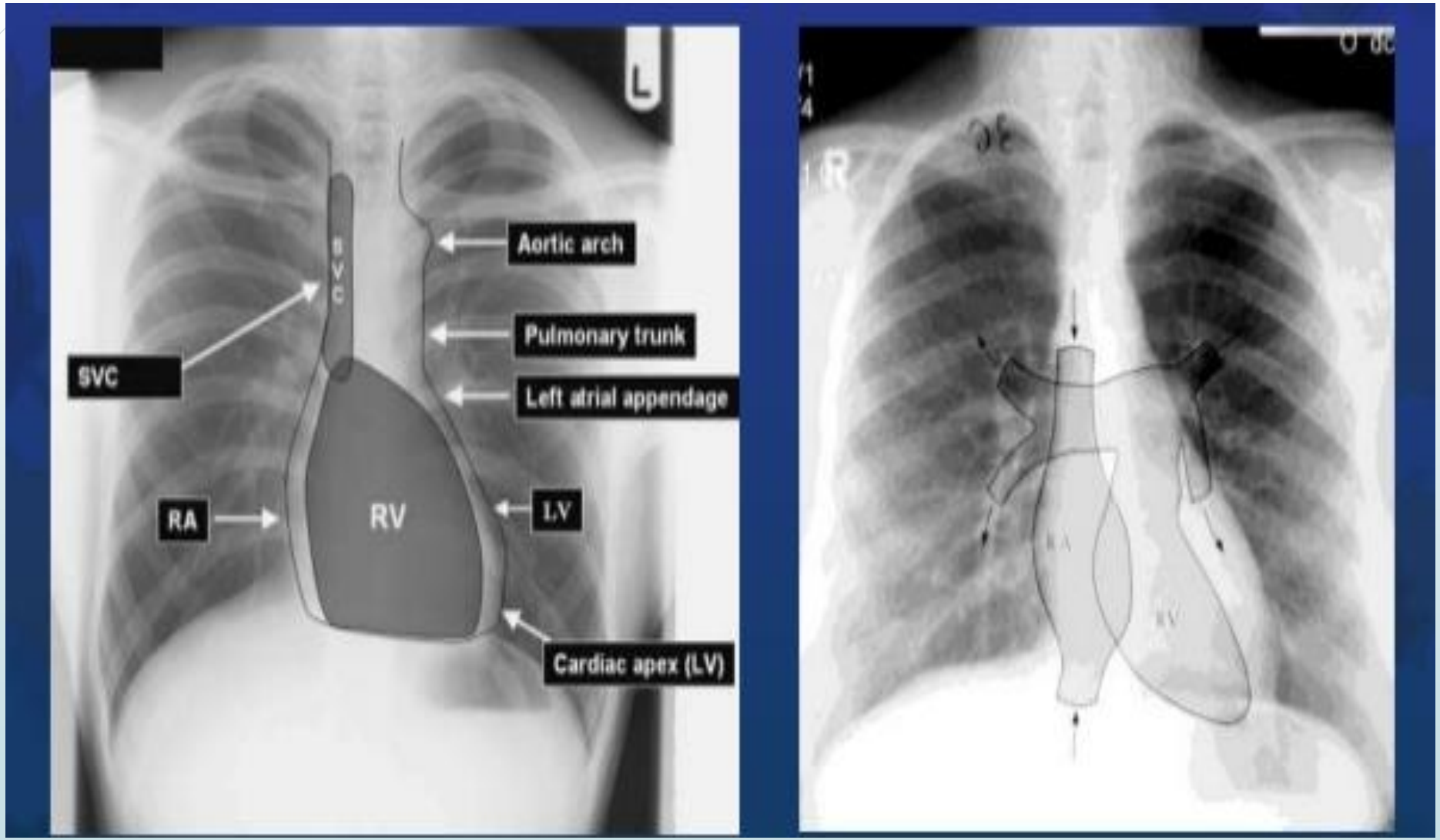

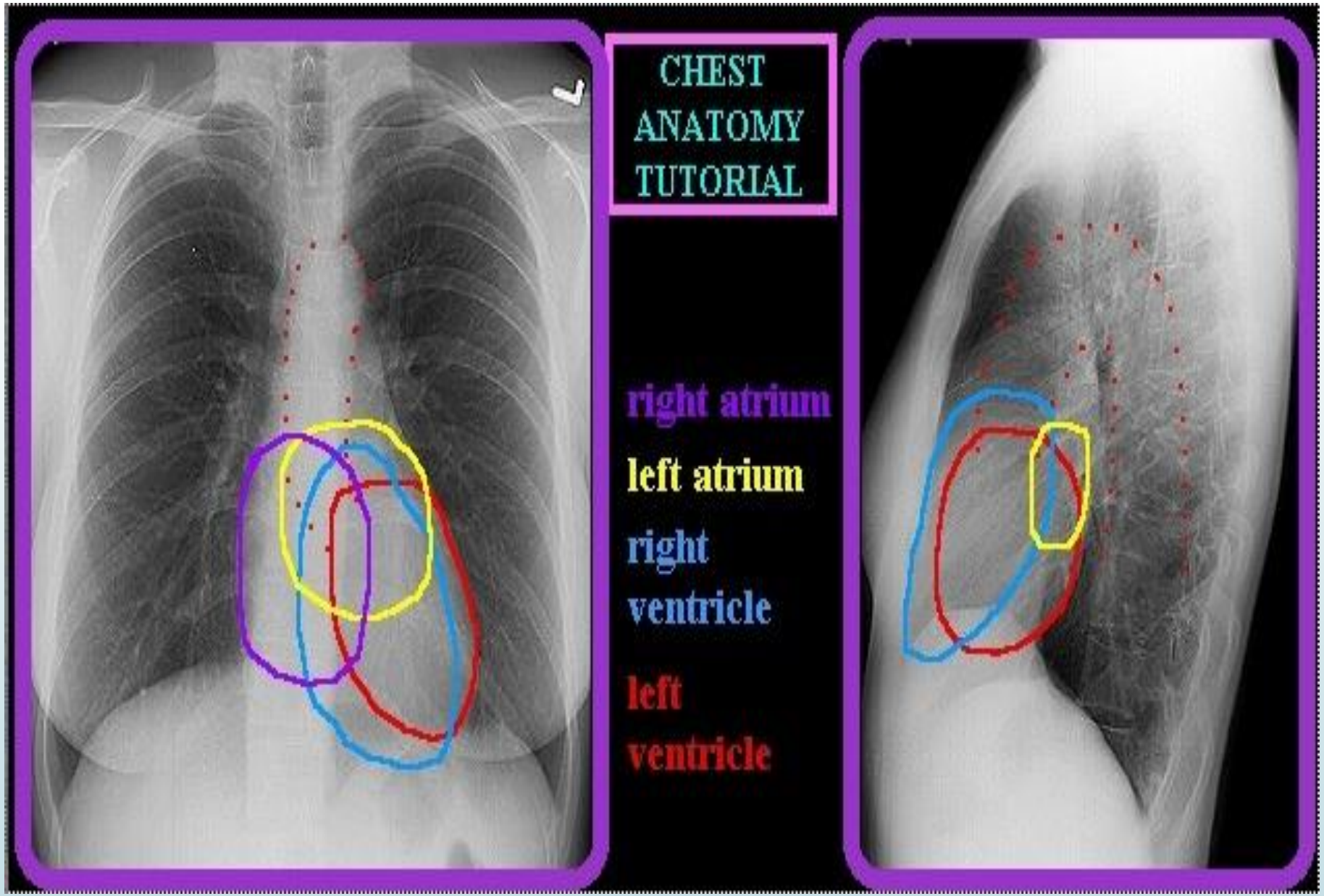
CHEST
ANATOMY
TUTORIAL
right atrium
left atrium
right
ventricle
left
ventricle

Lung Zones

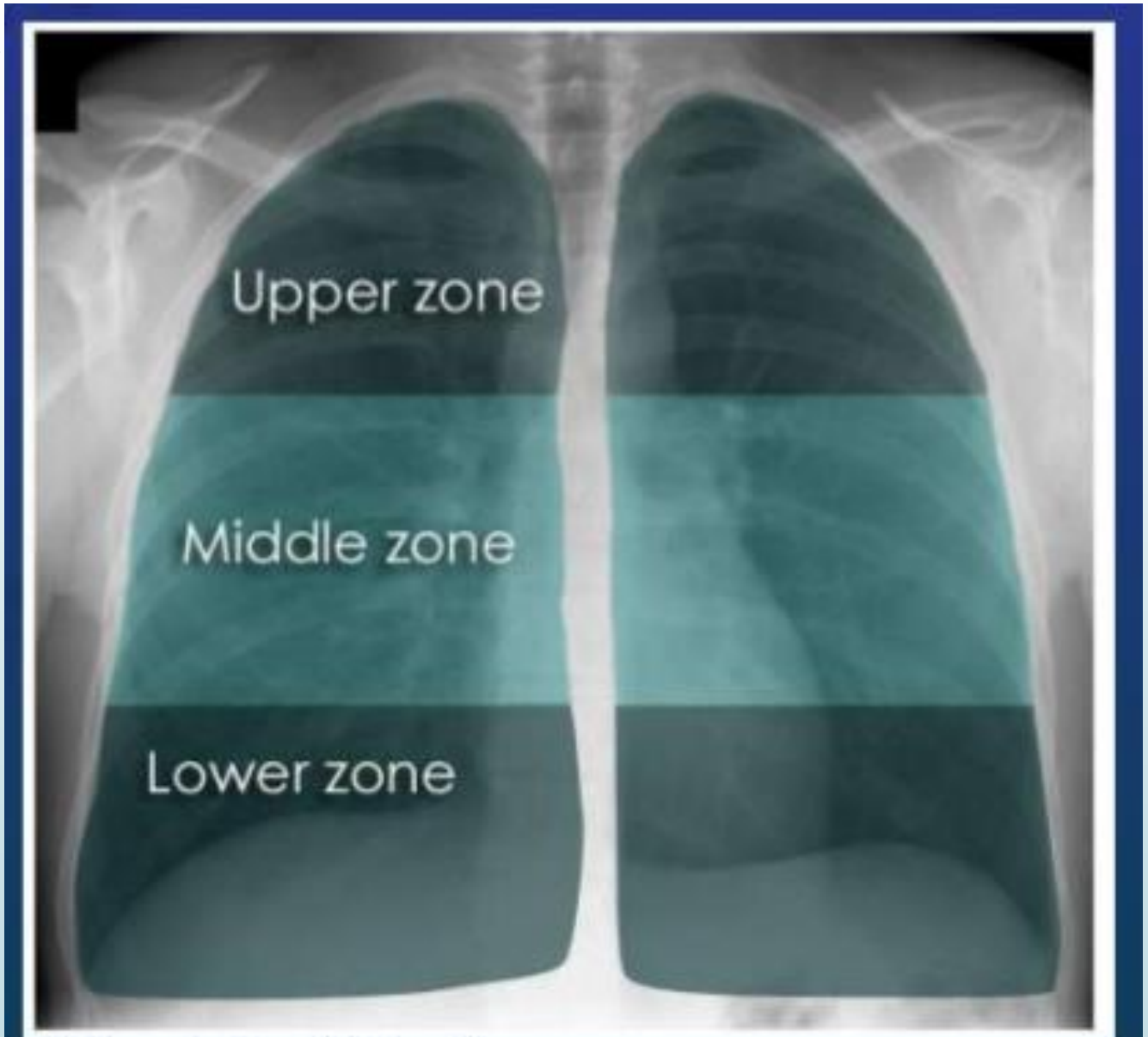

Each of these zones occupies approximately one third of the height of the lungs.

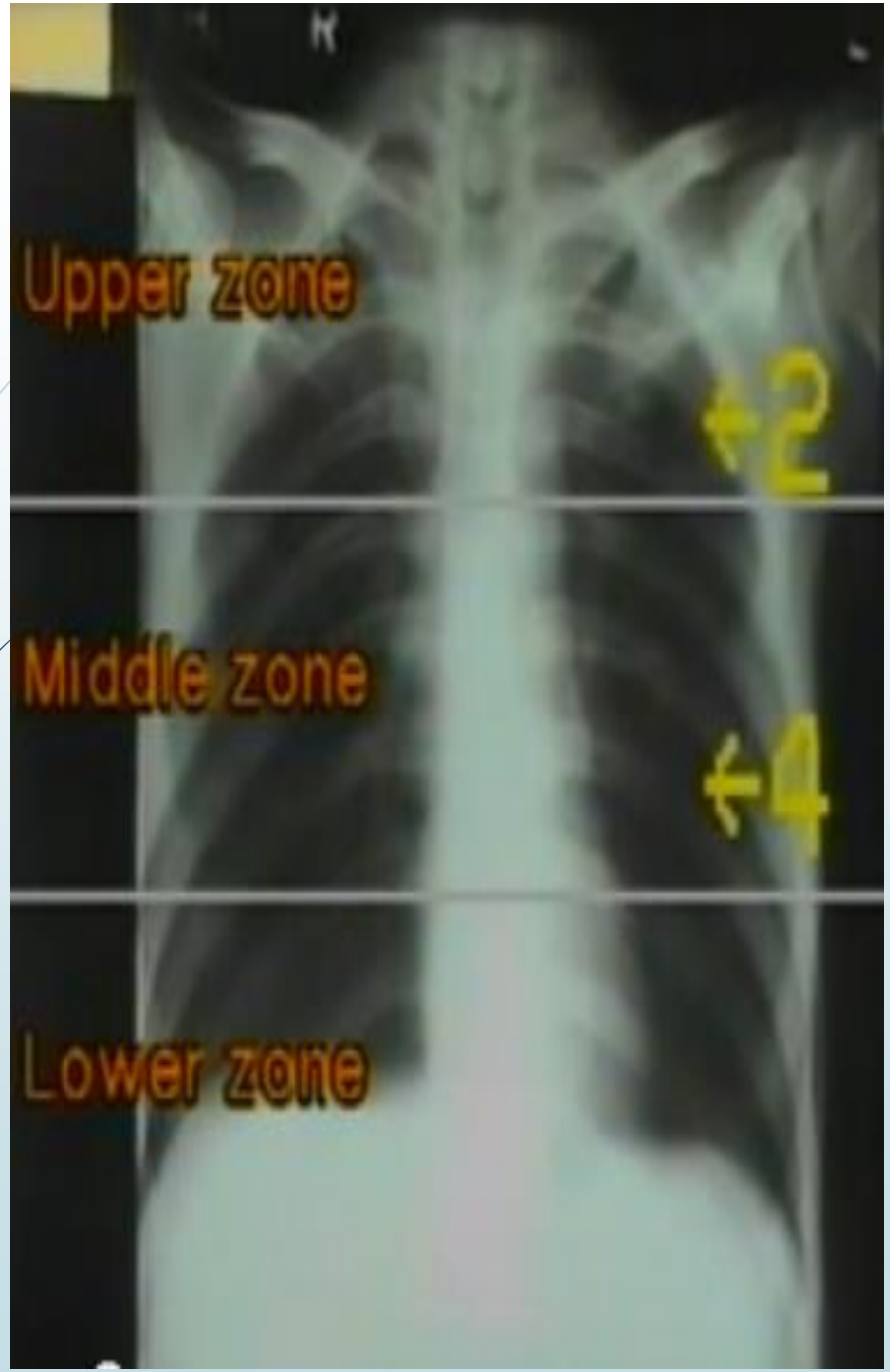
Upper zone
←2
Middle zone
←4
Lower zone

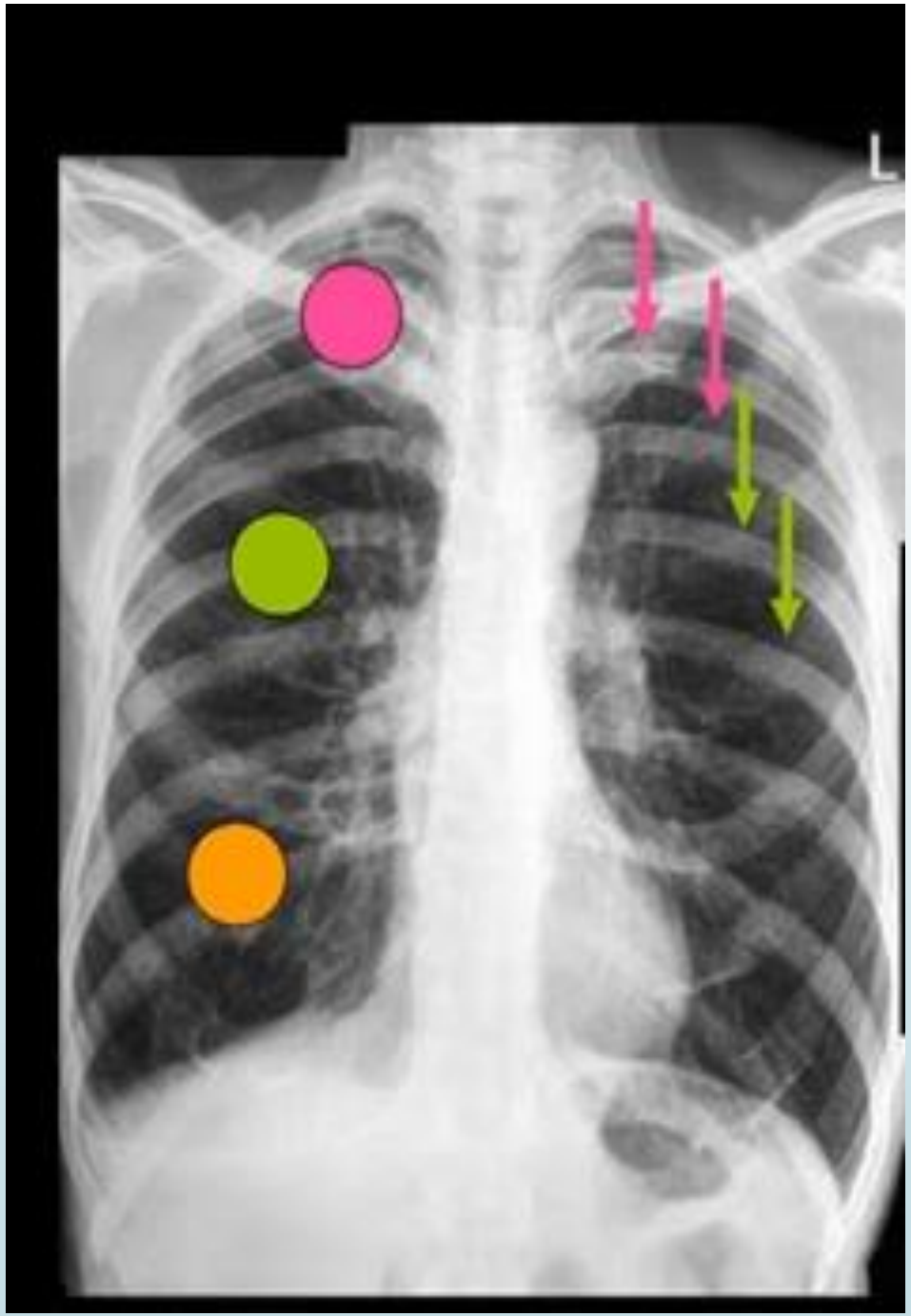


Lung Zones
Apical Zone
Upper Zone

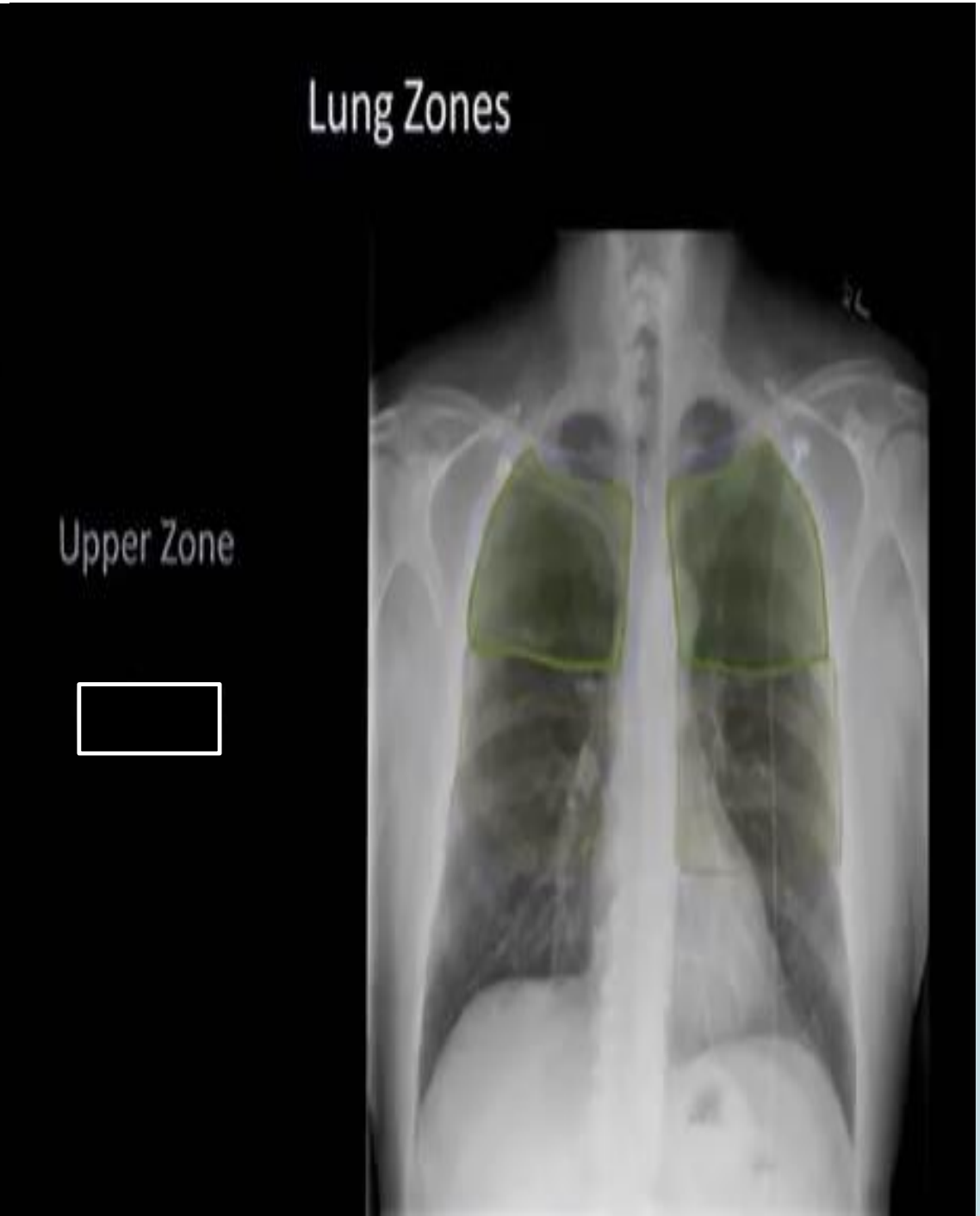
Lung Zones
Upper Zone


Lung Zones
Mid Zone
Lower Zone


Lung Zones
Lower Zone

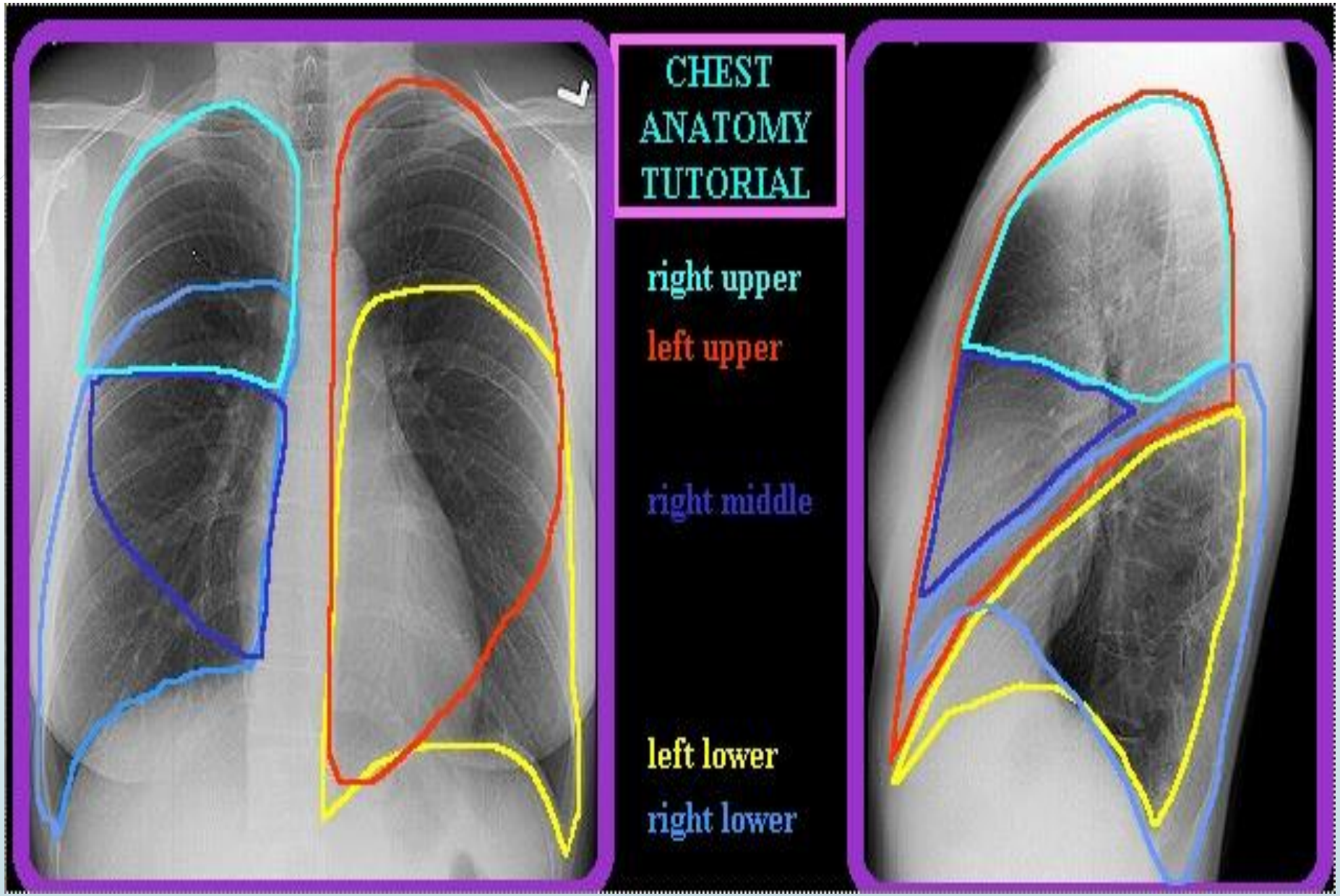
CHEST
ANATOMY
TUTORIAL
right upper
left upper
right middle
left lower
right lower

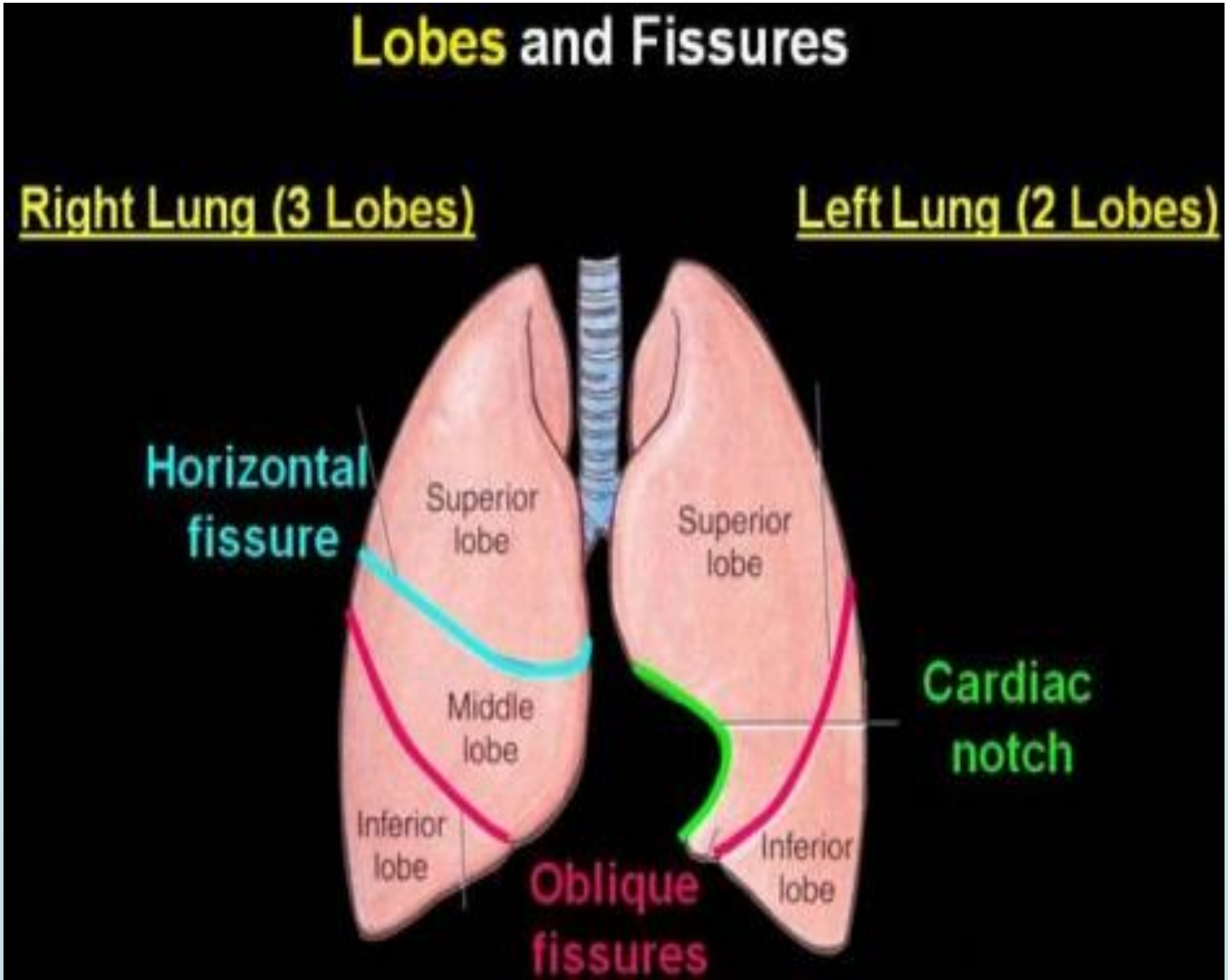
Lobes and Fissures
Right Lung (3 Lobes)
Left Lung (2 Lobes)
Horizontal fissure
Superior lobe
Middle lobe
Inferior lobe
Superior lobe
Inferior lobe
Cardiac notch
Oblique fissures

Right Lung lobe position.

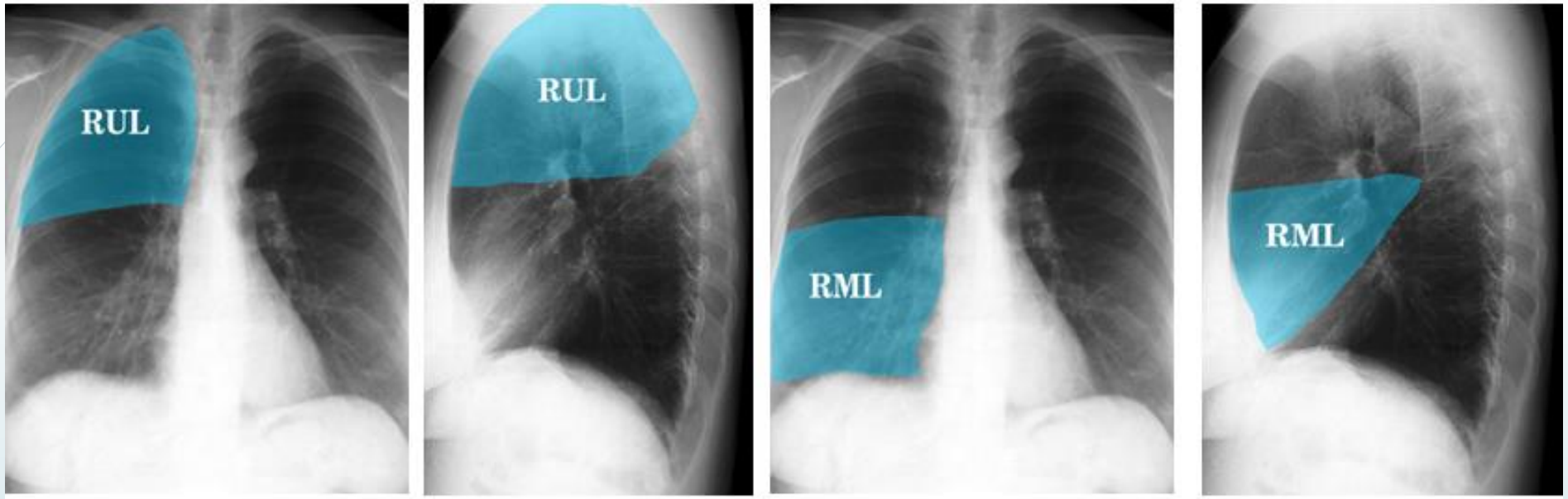

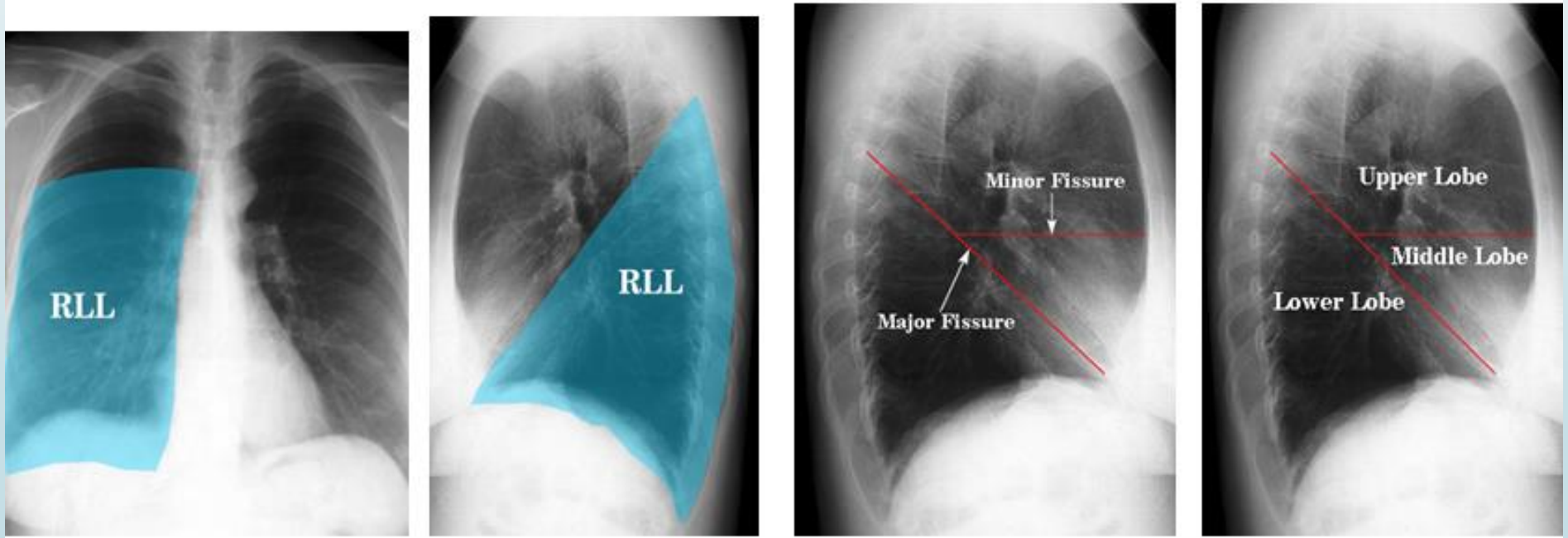

Left Lung lobe position.

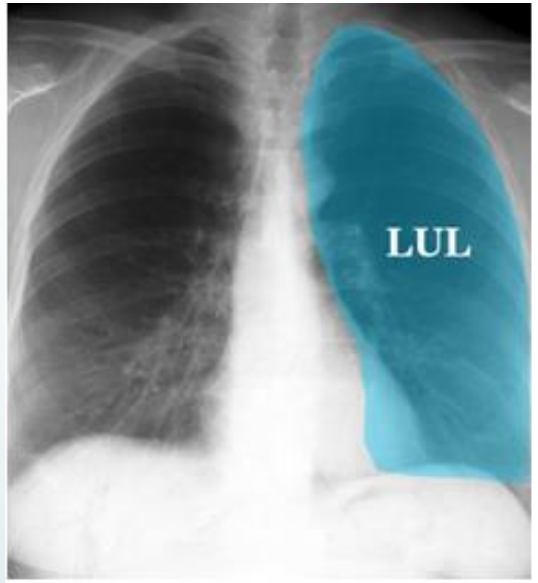

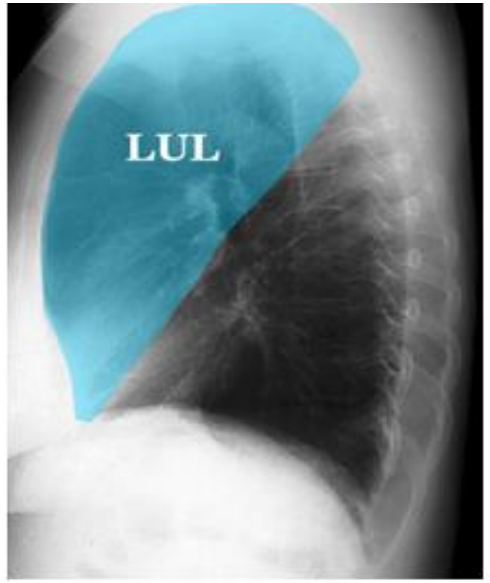

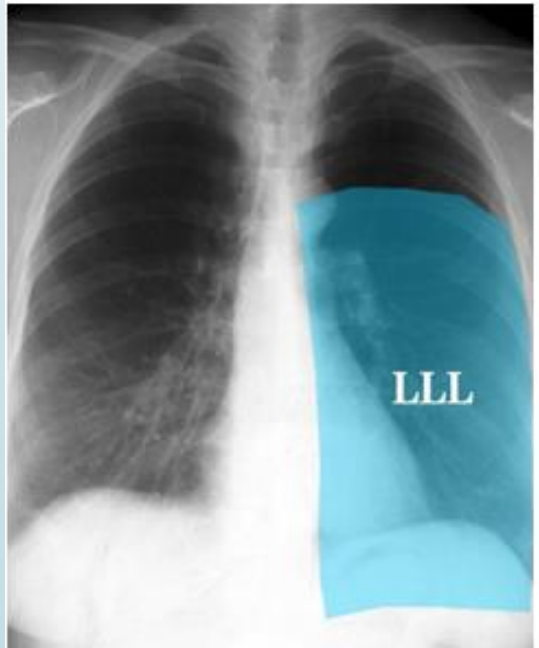

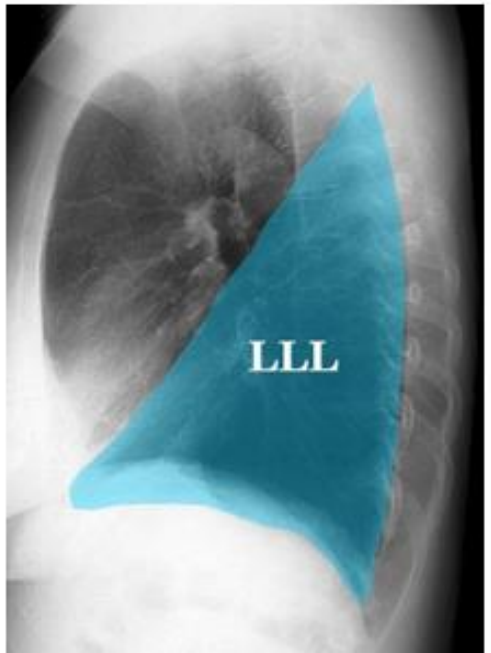

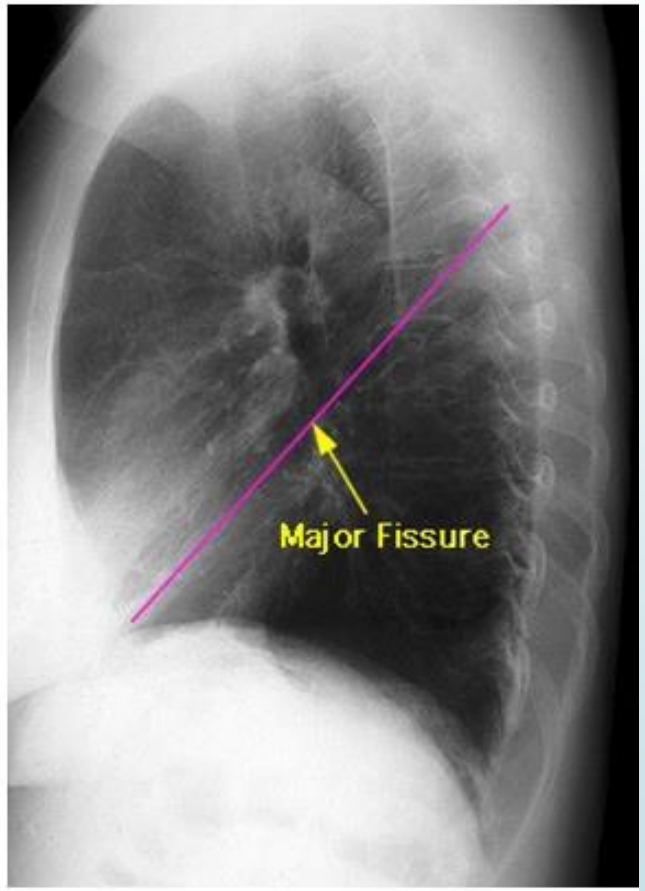

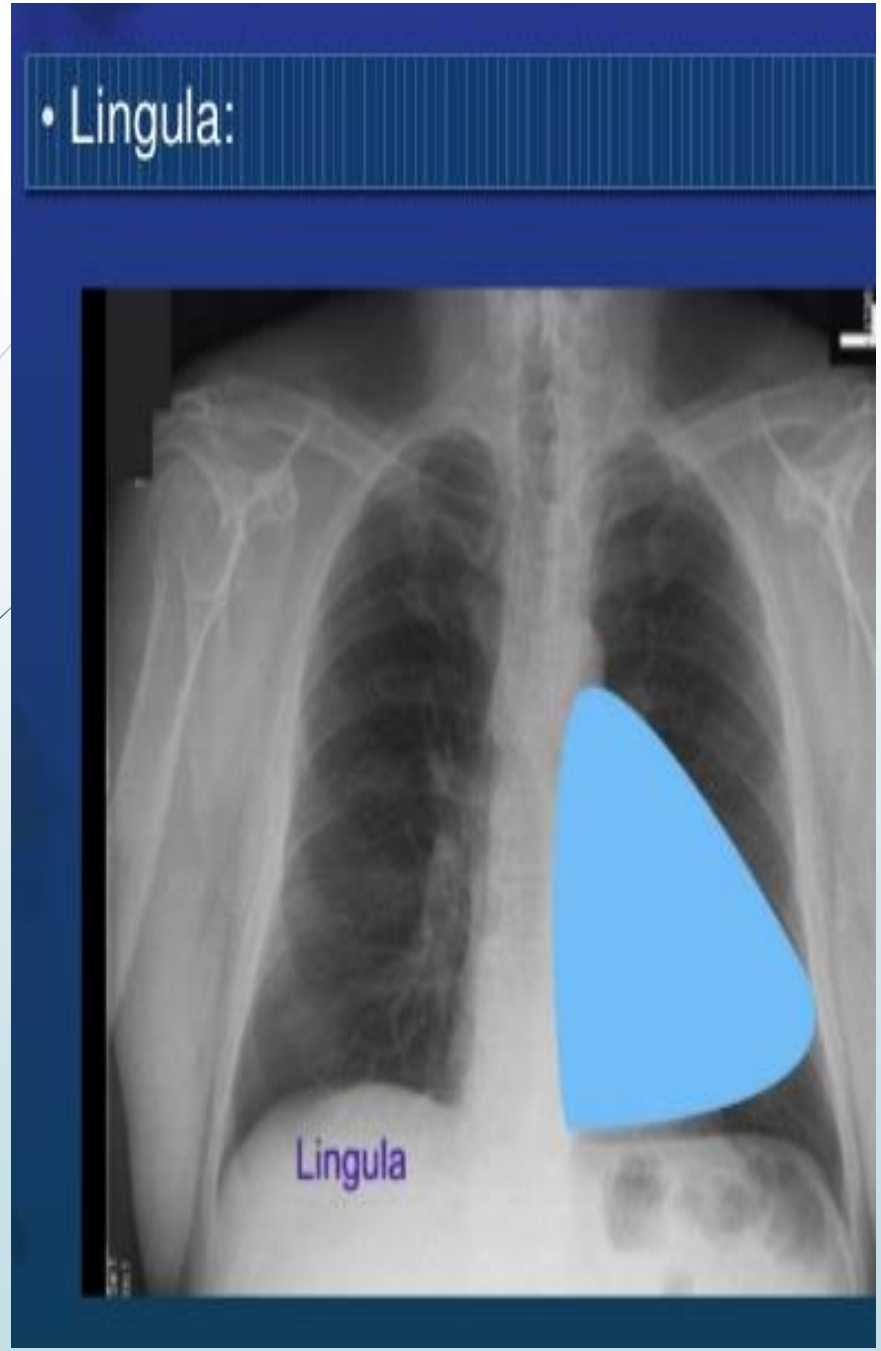
• Lingula:
Lingula

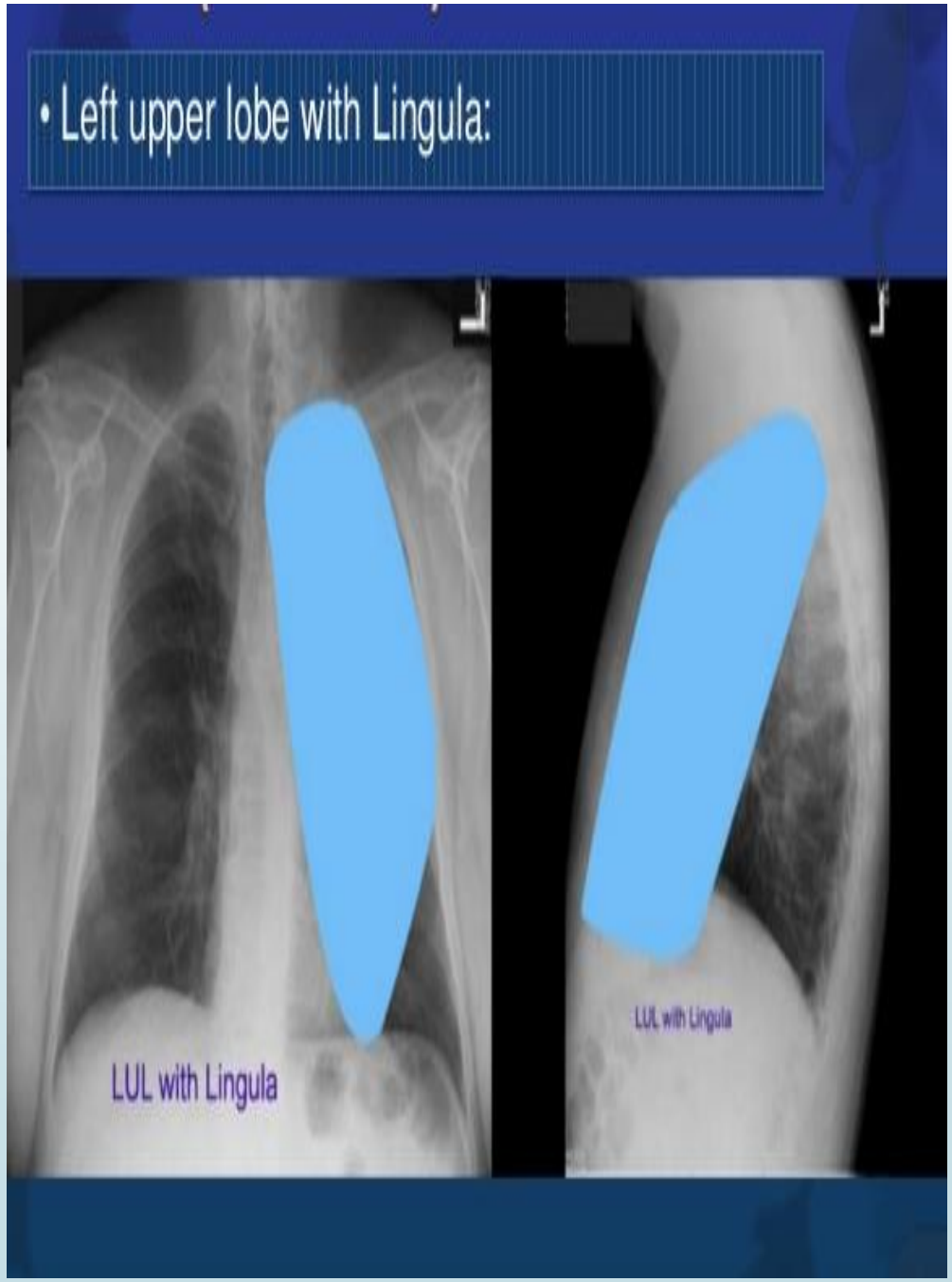
• Left upper lobe with Lingula:
LUL with Lingula
LUL with Lingula

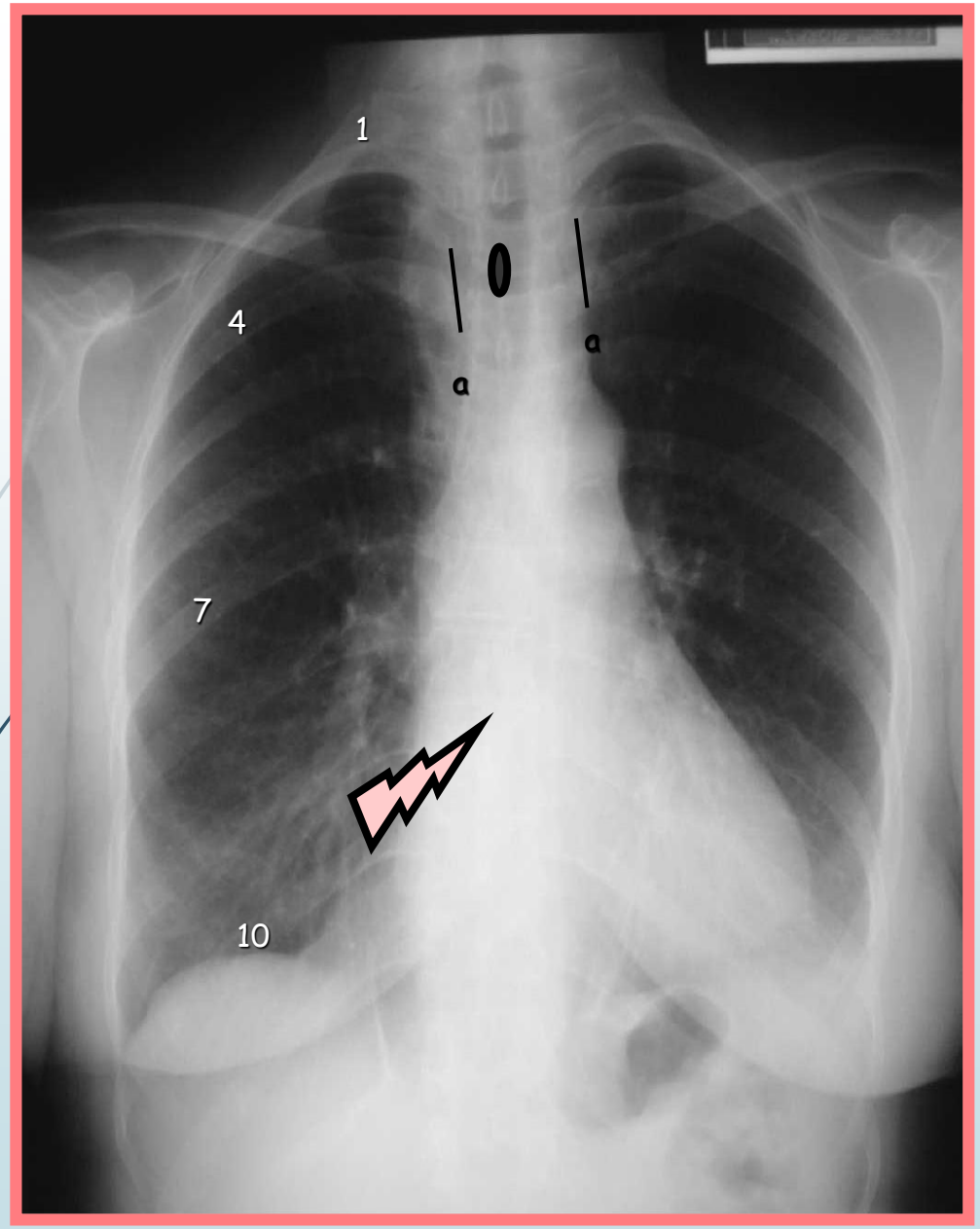

Postero-anterior view (PA)

Check Technique

1: Adequate penetration of the mediastinum-is the thoracic spine seen?

2: Has the patient taken a good inspiratory effort? About 8-10 posterior thoracic ribs should be seen through the lungs

3: Is there any rotation of the chest? Assessed by checking the upper thoracic spinous process (oval) in relation to the medial ends of the clavicles (lines 'a') - this CXR is rotated to left

Lateral View

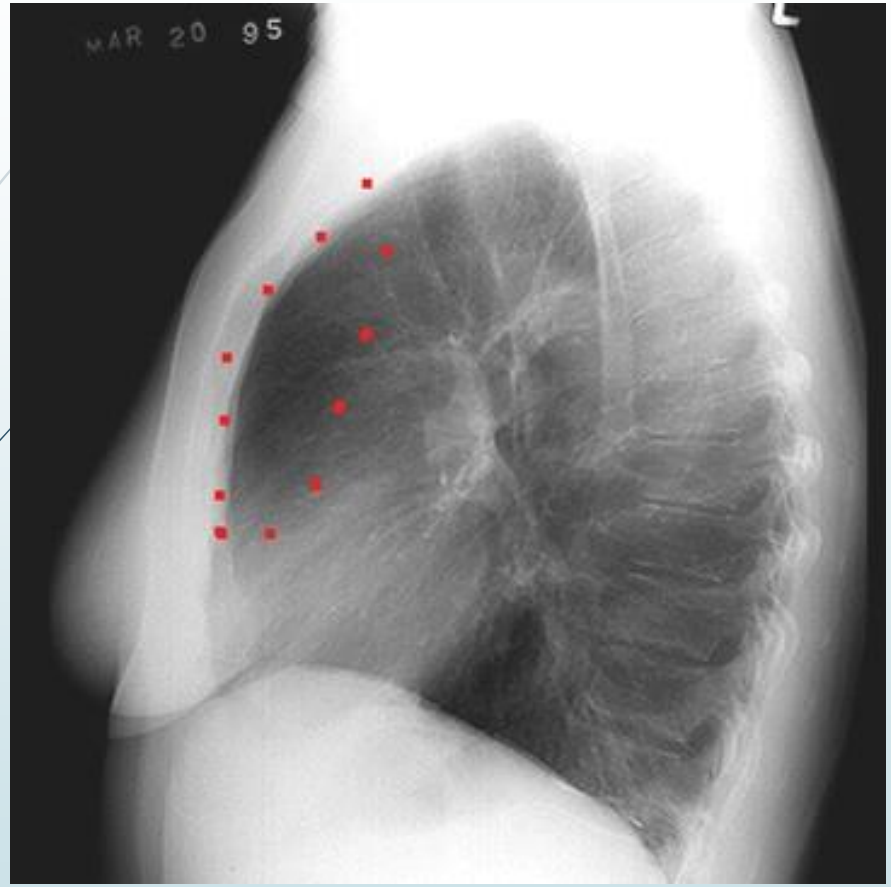

Retro sternal space

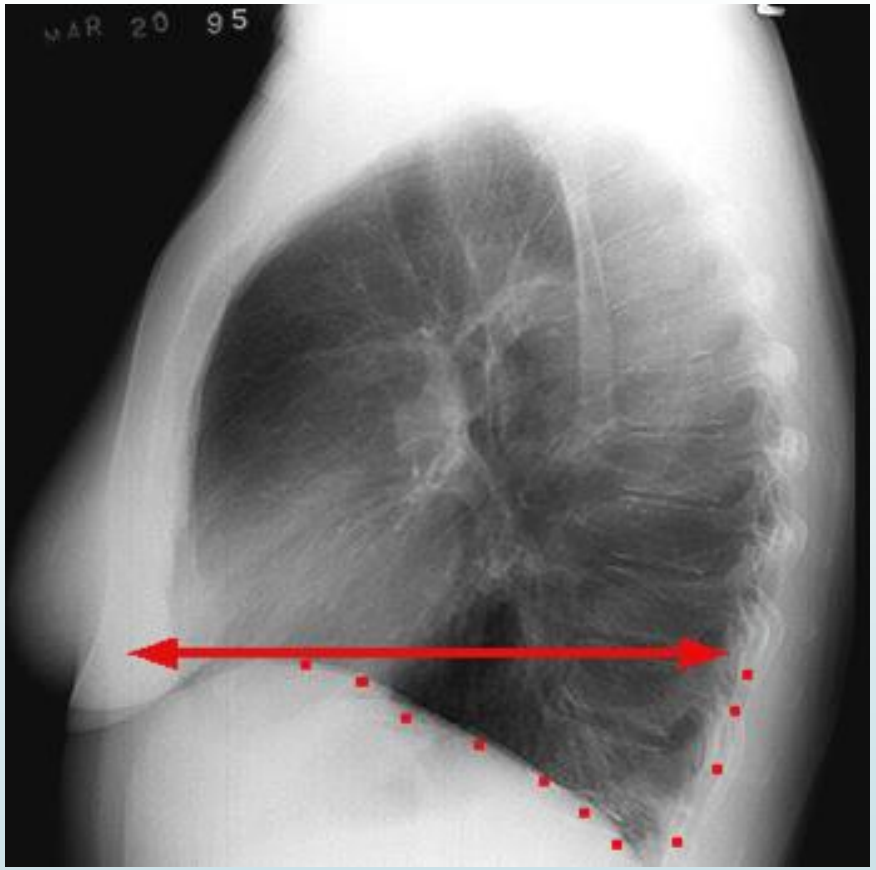

Retro cardiac space

Lordotic View

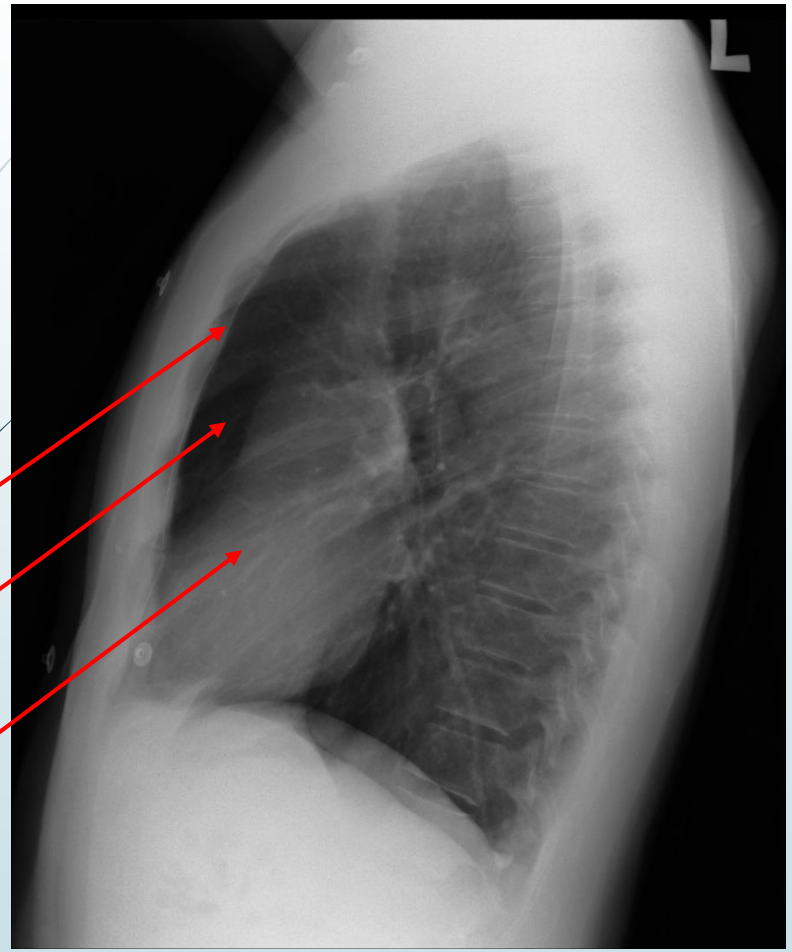

Better assess apices without bone overlap

Normal Chest X ray

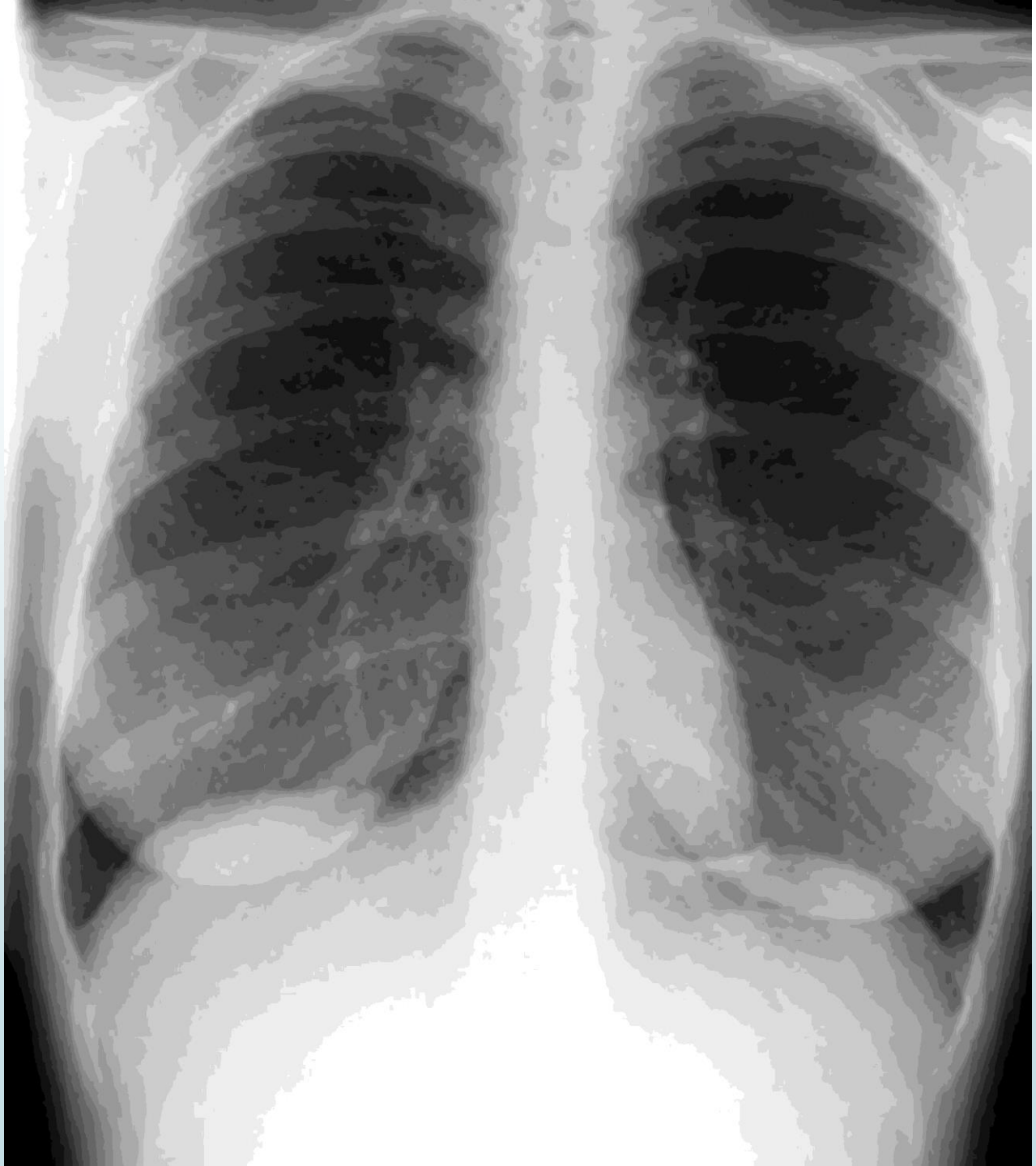

Abnormal Chest X-ray

- **Radiopacity** (whiteness) means increased density
- **Radiotranslucency** (blackness) means decreased density
- Radiopacity can be of 3 causes
  - Alveolar pattern – fluffy, soft, poorly demarcated opacifications < 1 cm in diameter
  - Possible causes:
    - Pulmonary edema
    - Viral pneumonia
    - Pneumocystis
    - Alveolar cell carcinoma

Lung pathologies

White Lung field

Black lung Field

Well defined

- ✓ Collapse
- ✓ Pleural Effusion

Ill defined

- ✓ Consolidation
- ✓ Fifrosis
- ✓ Pulmonary Edema
- ✓ Infiltration

Consolidation

- Replacement of air in one or more acini by fluid or solid material
- Smallest unit of consolidated lung is acinus casts 7mm diameter shadow
- Confluence occurs

Consolidation

- Causes
  - Pneumonia
  - Bronchial carcinoma
  - Lymphoma
  - Inflammatory conditions

Pneumonia (consolidation)

- Air bronchograms would confirm an alveolar process.
- The lung volume should not be lost (may even be increased).
- Usually all radiographic abnormalities should disappear after 6 weeks of appropriate antibiotic therapy.
- Radiological features
  - Airbronchogram
  - Silhouette sign
  - Lower border

The Silhouette Sign

- Two substances of same density, in direct contact, can not be differentiated from each other on an x-ray.This phenomenon, the loss of normal radiographic silhouette(contour), is called the silhouette sign.

Silhouette sign

Right heart border	Anterior
Descending aorta	Posterior
Left heart border	Anterior
Ascending aorta	Anterior
Aortic knob	Mid posterior

Silhoutte sign

Silhoutte	Adjacent organ or segment
Diaphragm	LL basal segments
Right heart border	RML Pathology
Ascending aorta	RUL anterior segment
Aortic knob	LUL apico posterior segment
Left heart border	Lingular pathology
Descending aorta	Left lower lobe apical

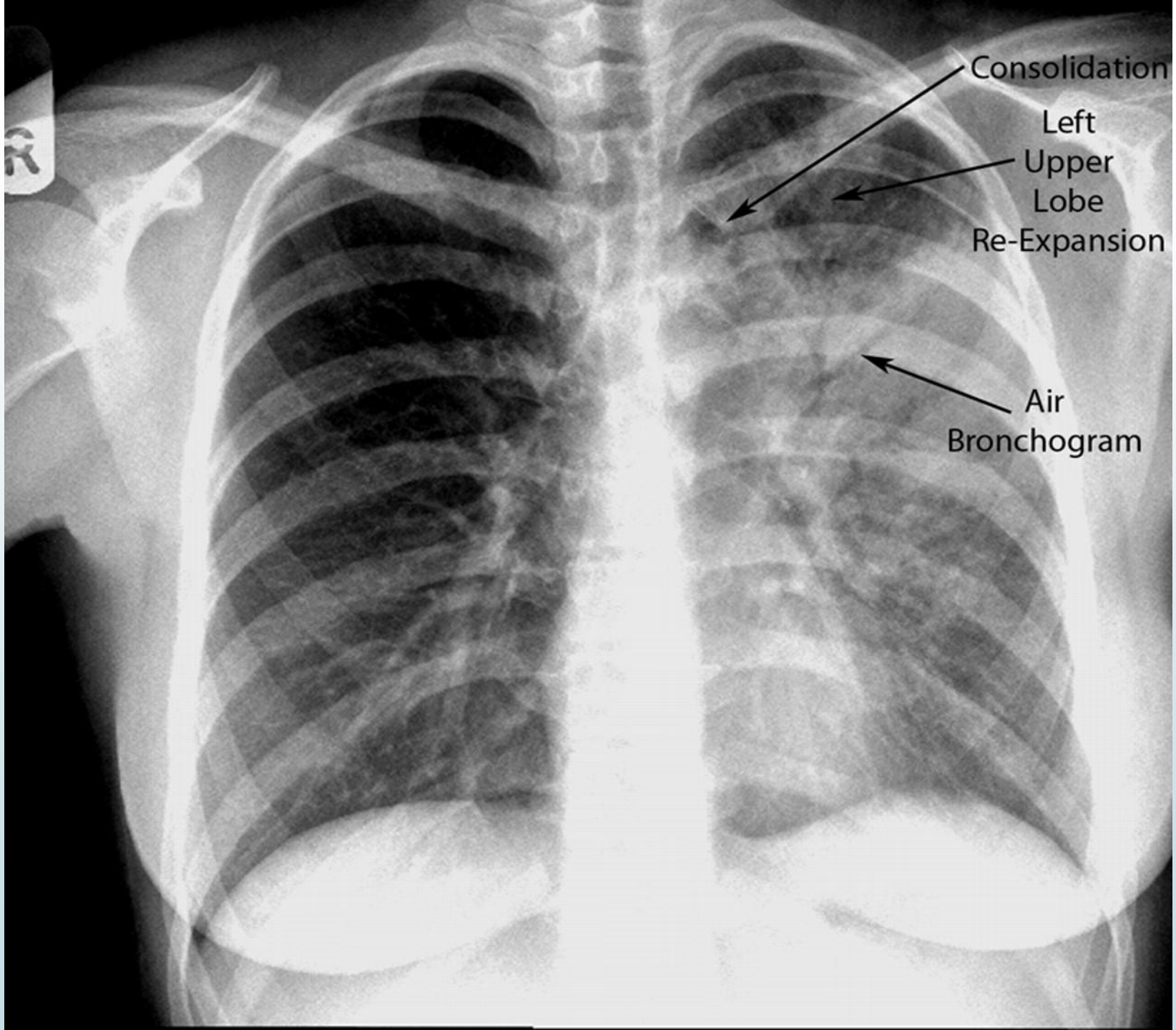
Consolidation
Left
Upper
Lobe
Re-Expansion
Air
Bronchogram

- When consolidation is associated with patent conducting airway an air bronchogram is seen. It is produced by contrast between the column of air in the airway and surrounding opaque acini

- If consolidation is secondary to bronchial obstruction affected area is of unifrom density with no air bronchograms.

- **VOLUME OF THE LUNG IS NORMAL UNLIKE COLLAPSE**

- RUL consolidation is confined by horizontal fissure inferiorly and upper half of oblique fissure posteriorly ,may obscue right upper mediastinum

RUL Consolidation

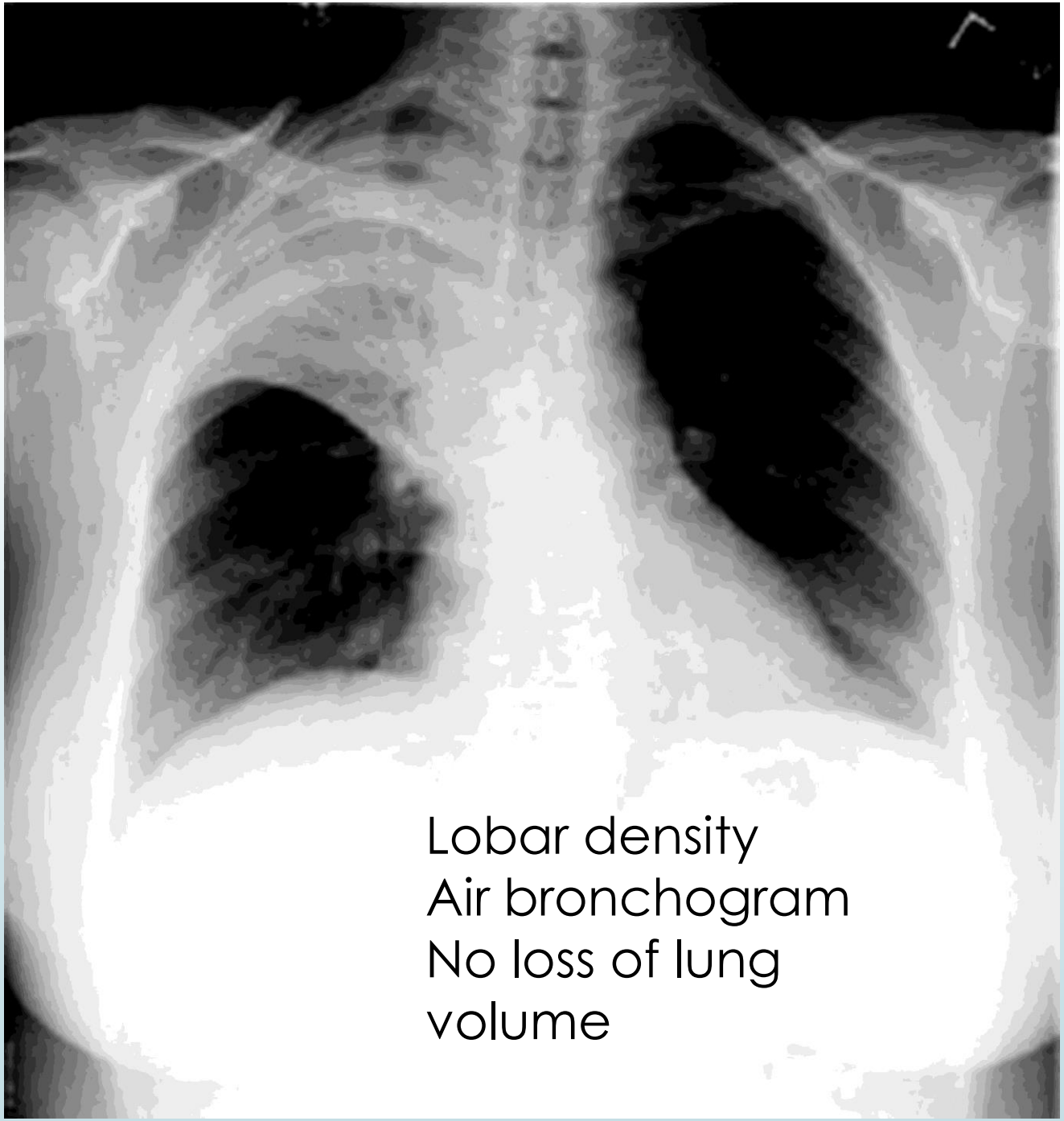

RUL Consolidation

- Density in right upper lung field
- Lobar density
- Loss of ascending aorta silhouette
- No shift of mediastinum
- Transverse fissure not significantly shifted
- Air bronchogram

Right Upper Lobe Pneumonia

- RML consolidation is limited by horizontal fissure above and lower half of oblique fissure posteriorly ,may obscure right heart border

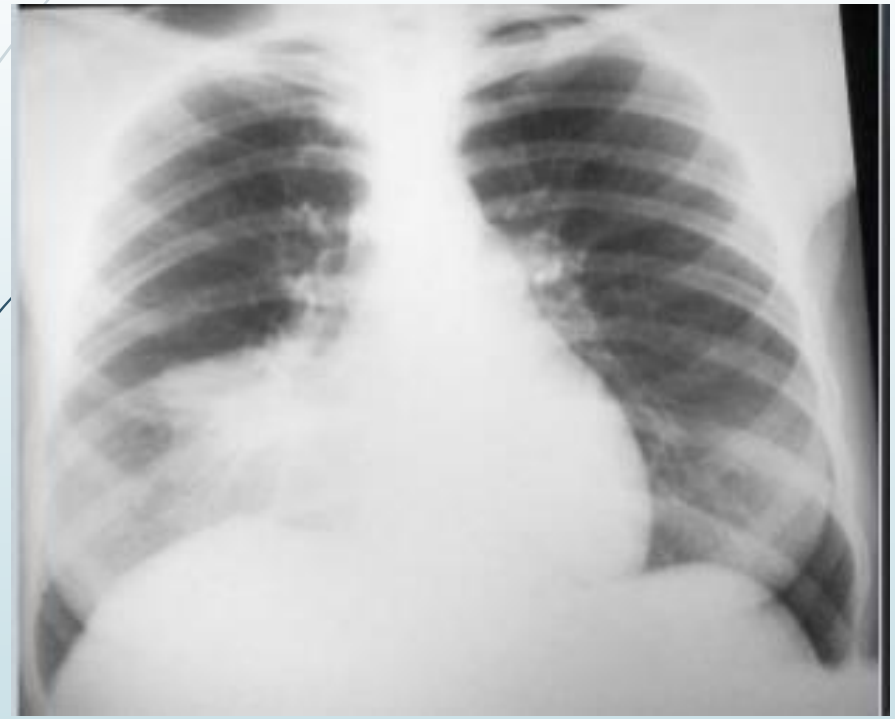

Right Middle lobe Pneumonia

Right Middle lobe Pneumonia

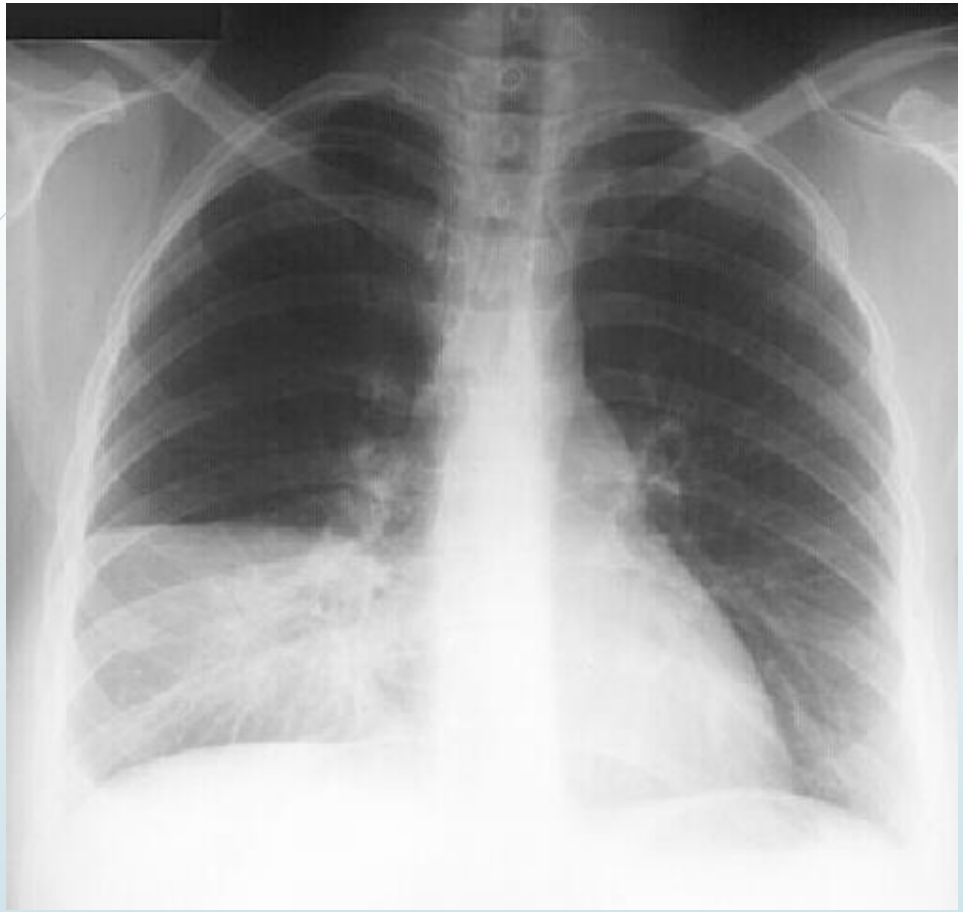

- ✓ The right heart border is not seen as it is silhouetted by a soft tissue density, right Hemidiphragm is seen.
- ✓ On lateral view triangular density overlying the heart in front of oblique fissure confirms it to pneumonia right middle lobe.
- ✓ No loss of volume.

- Lower lobe consolidation is limited by oblique fissure anteriorly and may obscure diaphragm

Right Lower Lobe pneumonia

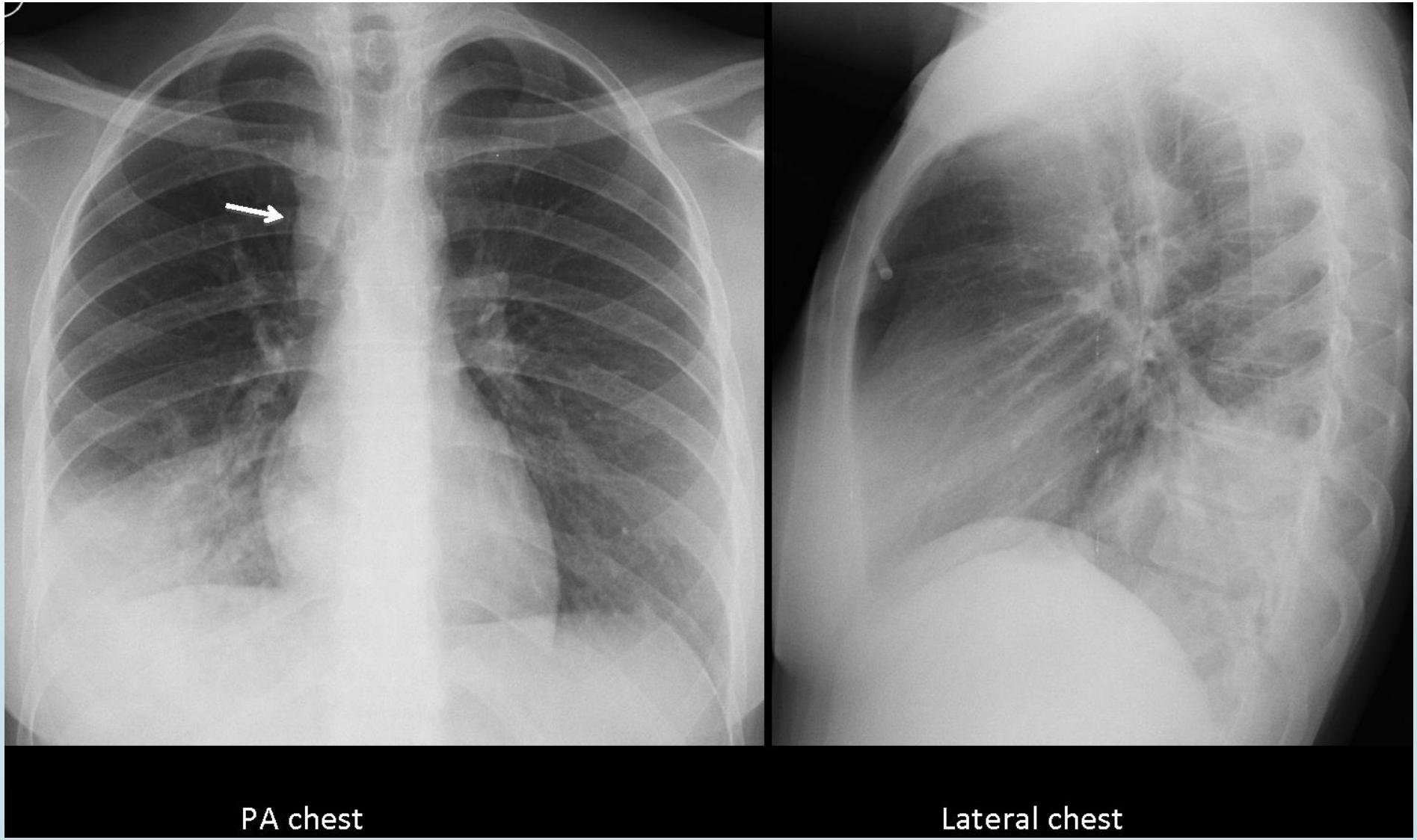

LUL and lingula consolidation

- These are limited by oblique fissure posteriorly ,lingular consolidation may obscure left heart border, consolidation of upper lobe may obscure aortic knuckle.

Left Upper Lobe Consolidation

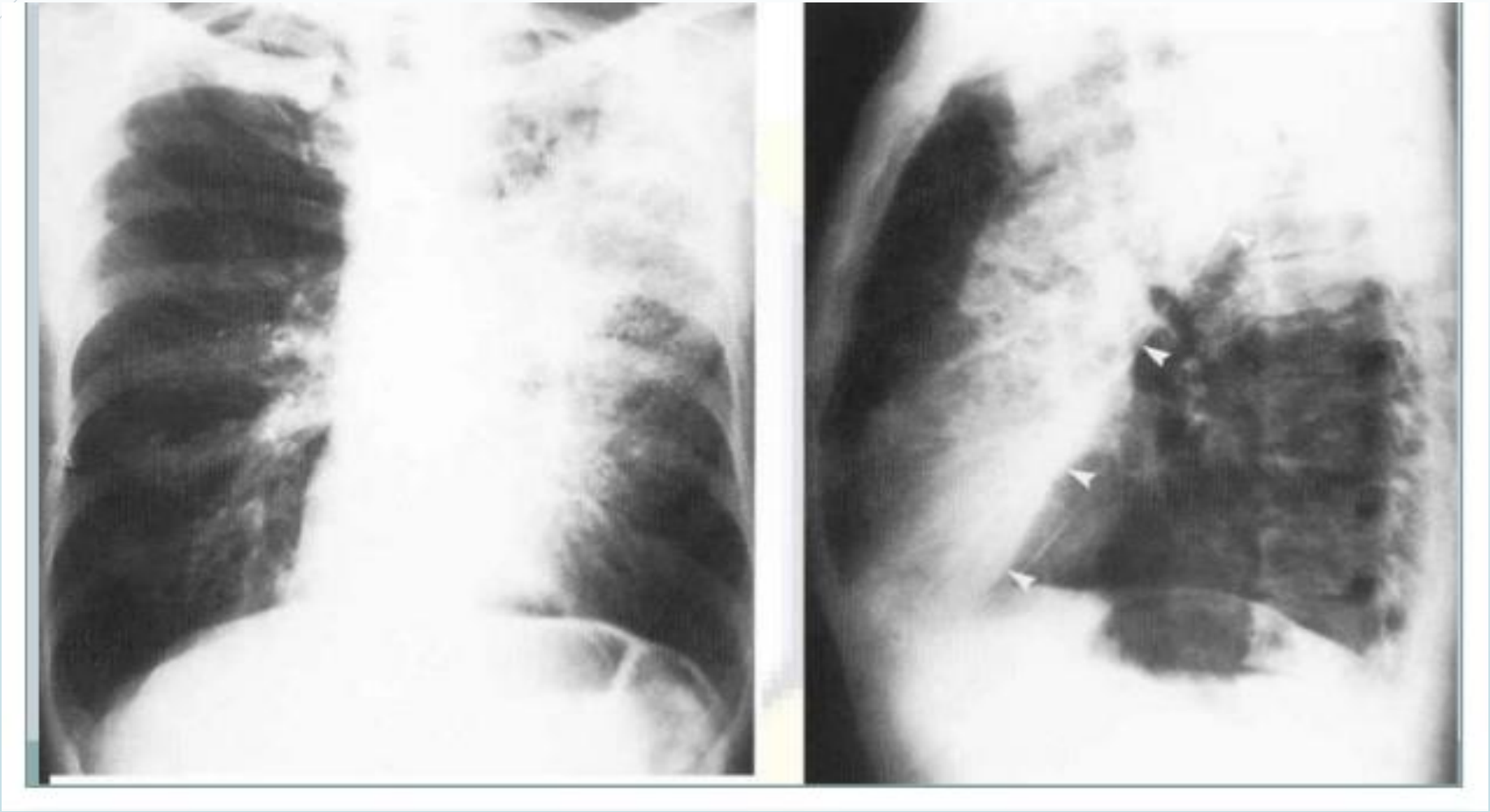

Left Upper Lobe Pneumonia

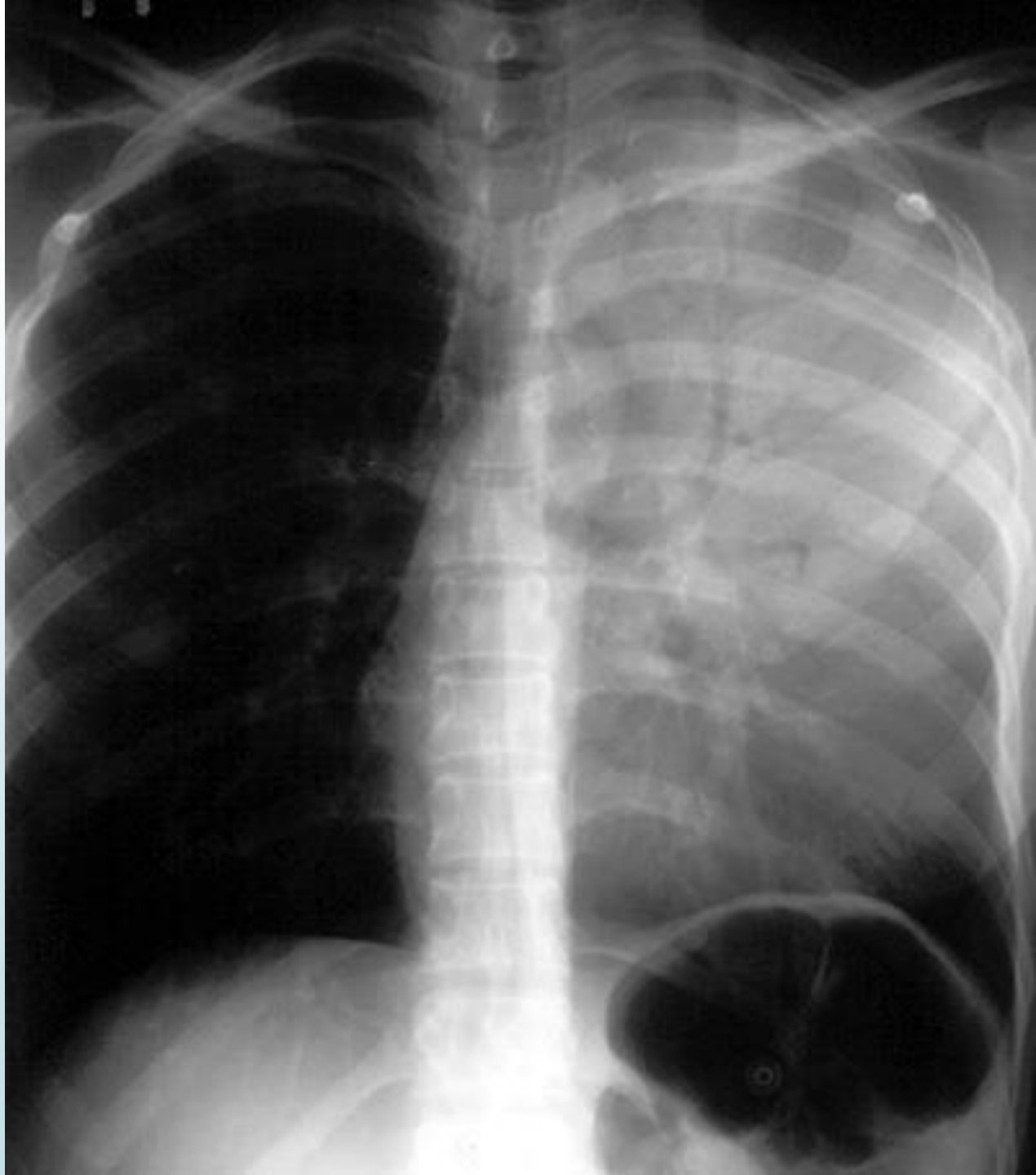

Lingular pneumonia

Left Lingular Pneumonia

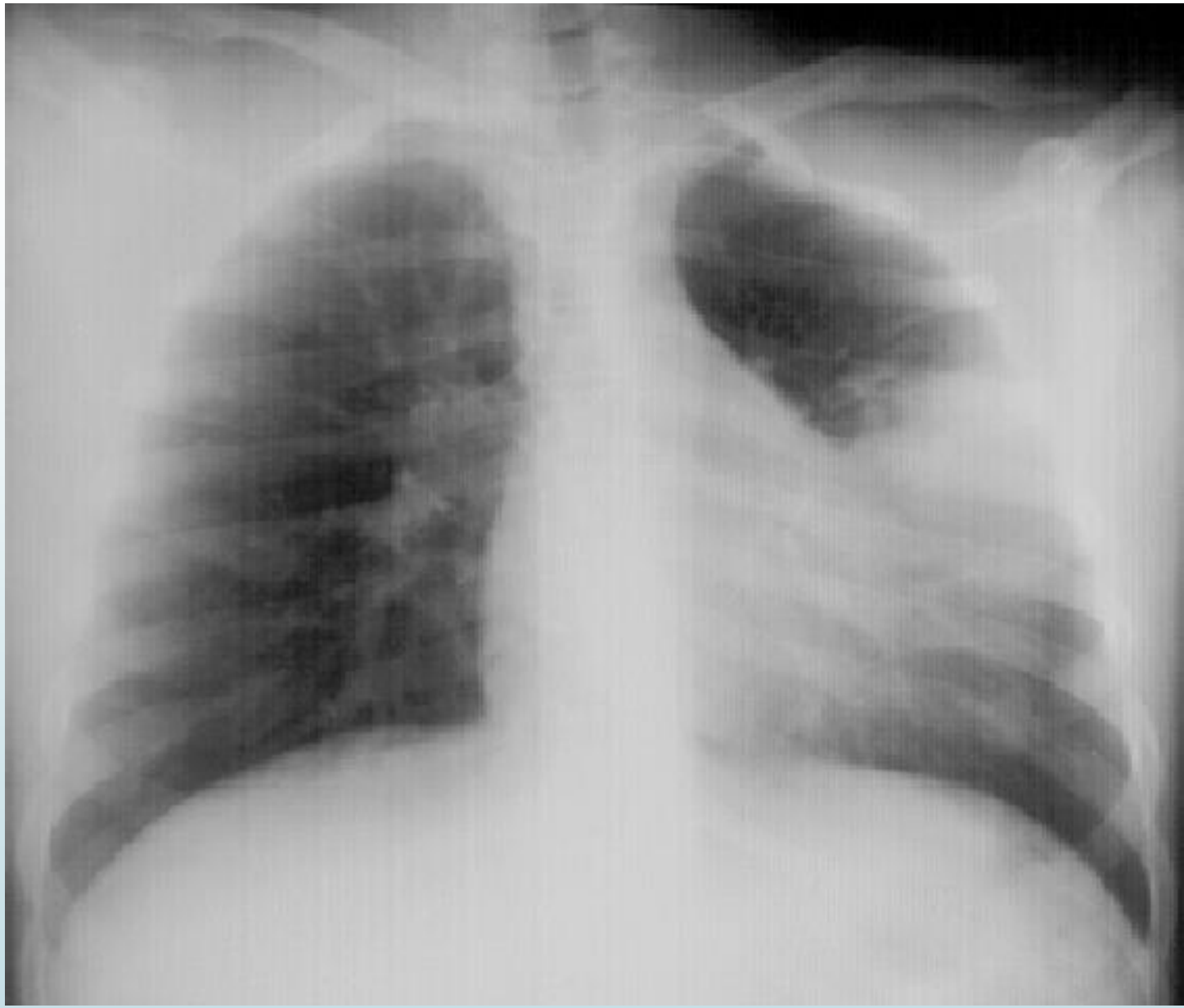

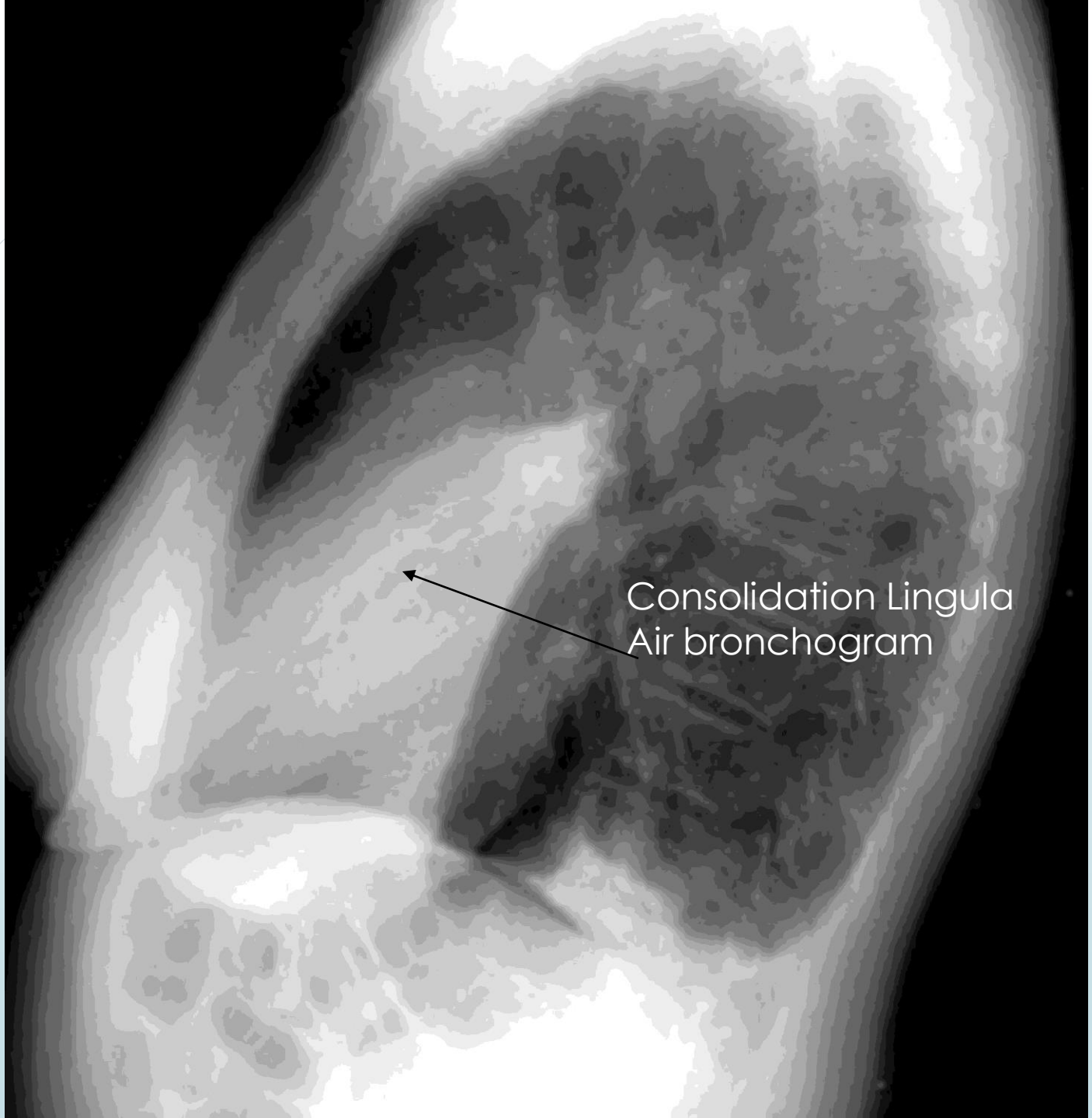

Left Lingular Pneumonia

Left Lower Lobe Pneumonia

Left Lower Lobe Consolidation

- Density in left lower lung field
- Loss of left heart silhouette
- Diaphragmatic silhouette intact
- No shift of mediastinum
- Blunting of costophrenic angle

Pattern of Consolidation on Plain Film

Round Pneumonia

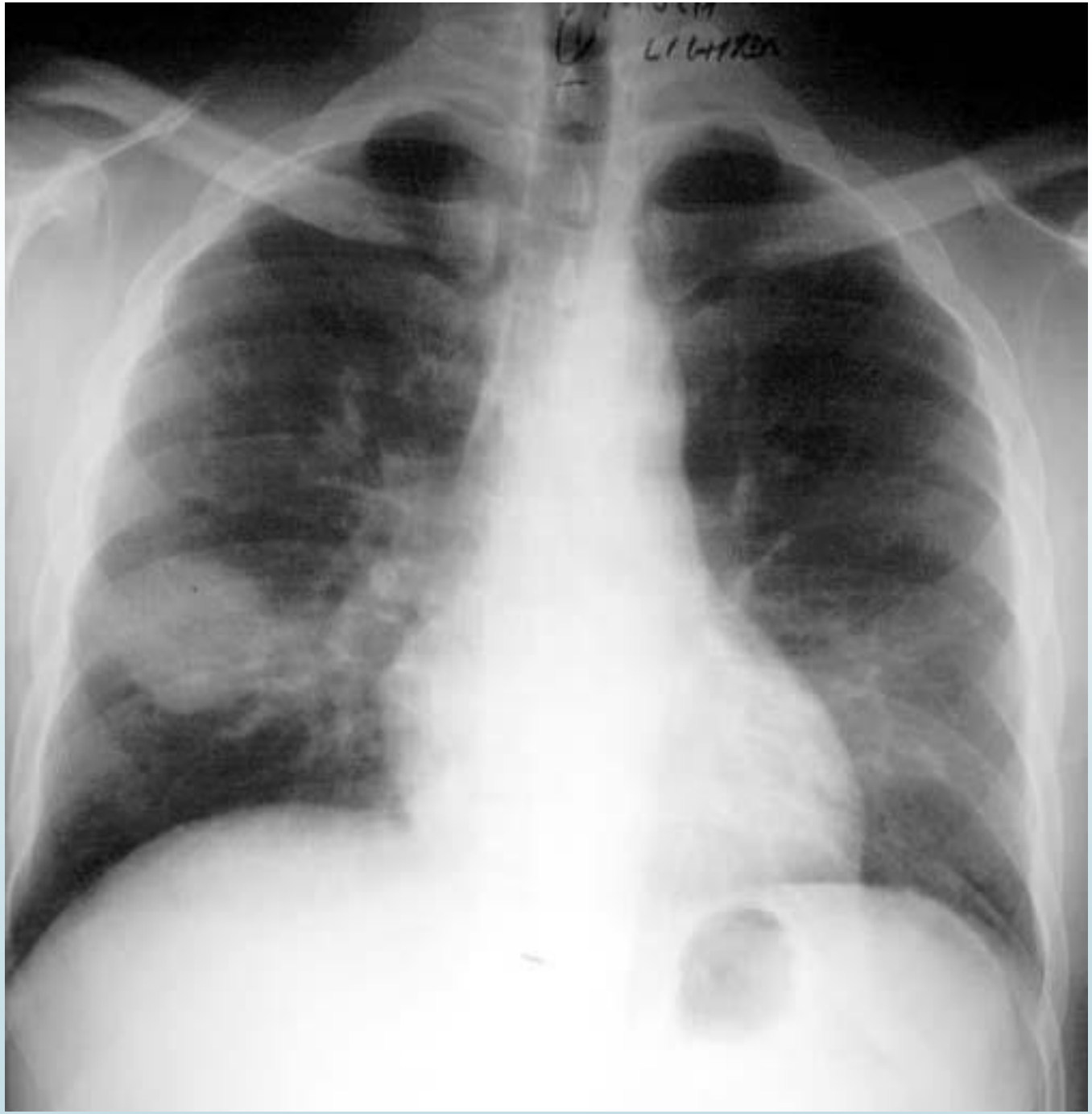

Consolidation and follow-up X-rays

- Resolution of the X-ray signs always lags behind the clinical findings
- The X-ray should therefore be repeated 4 weeks later to check for resolution.
- If there is persistent consolidation at this stage, further investigation is necessary to exclude an obstructive lesion.

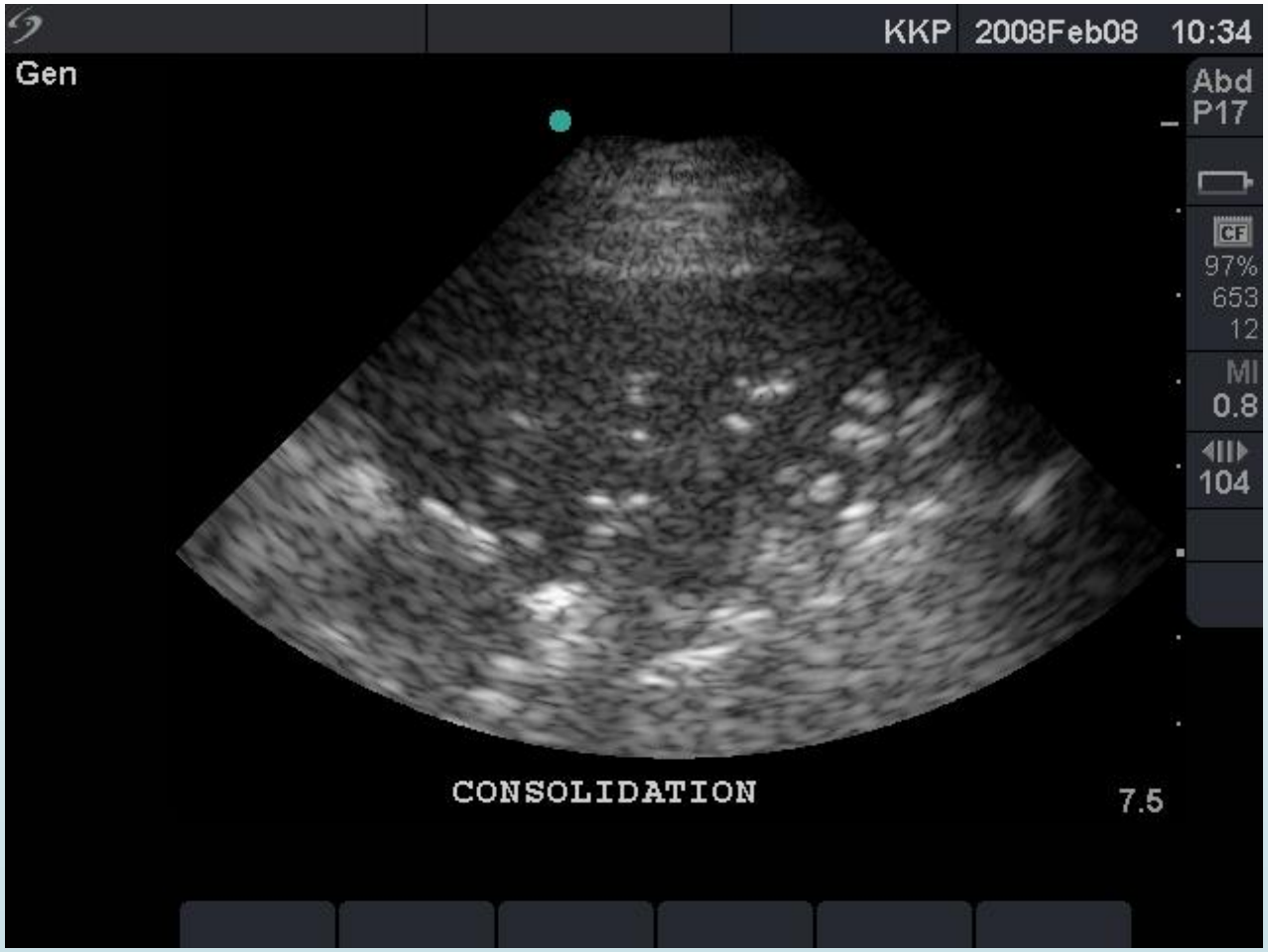
KKP 2008Feb08 10:34
Gen
Abd
P17
CF
97%
653
12
MI
0.8
104
CONSOLIDATION
7.5

OPACITY WITH AIR BRONCHGRAMS

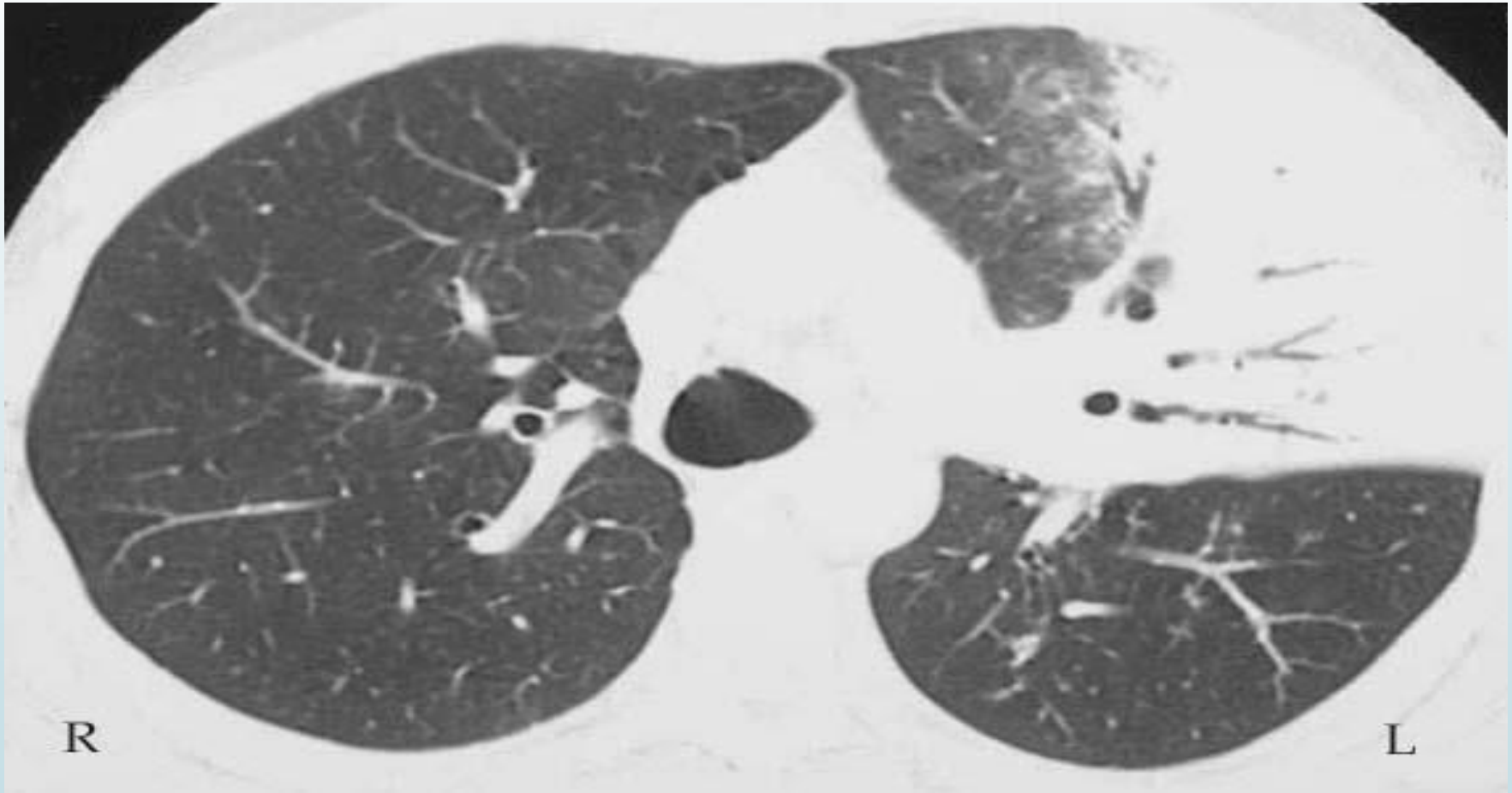

Lung Collapse

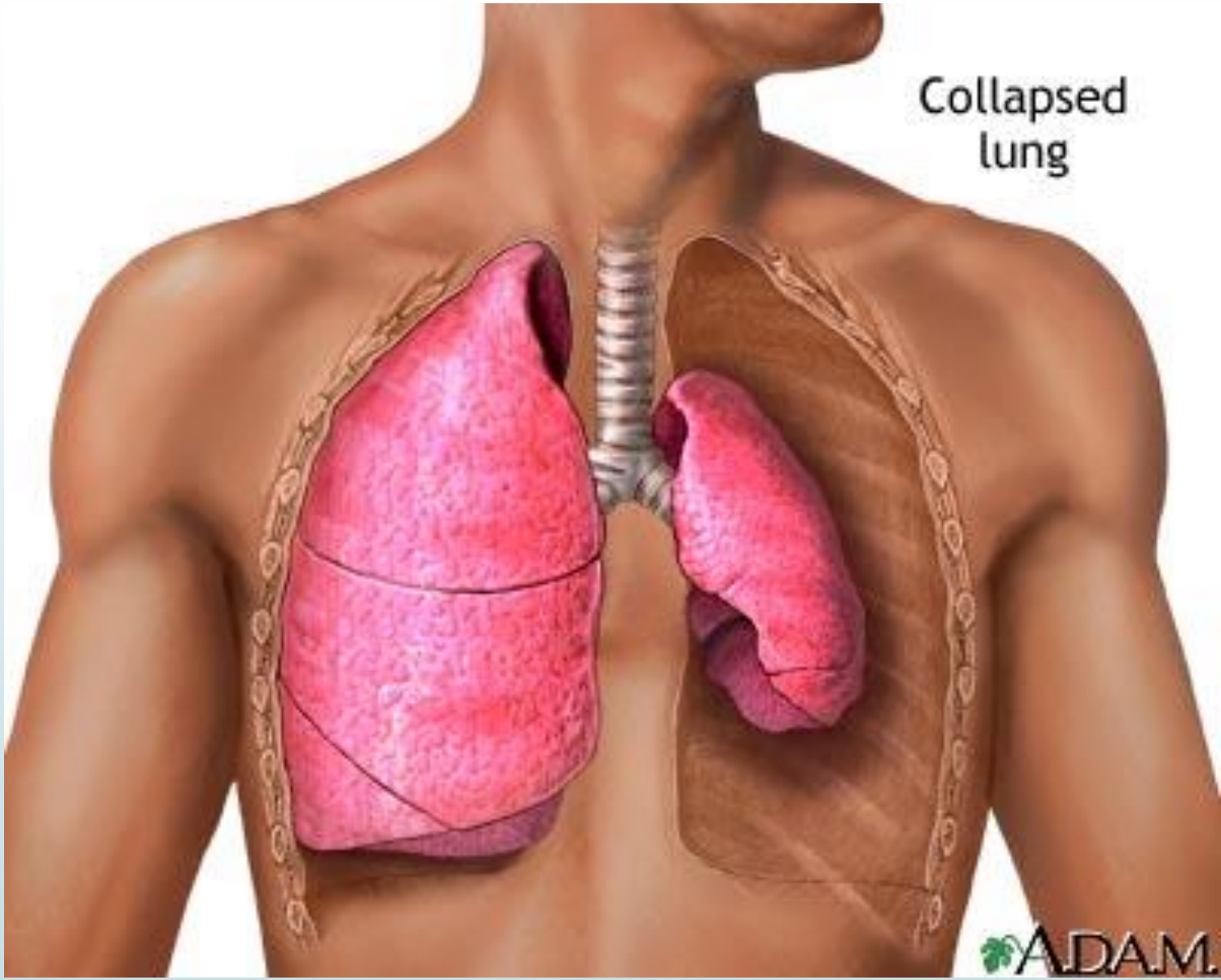

Lung Collapse

Collapse is diminished volume of air in the lung with associated reduction of lung volume and in consolidation there is diminished volume of air in the lung associated with normal lung volume

MECHANISMS OF COLLAPSE

- 1)Relaxation or passive collapse
- 2)Cicatrization collapse
- 3)Adhesive collapse
- 4)Resorption collapse

SIGNS OF COLLAPSE

DIRECT SIGNS:

- Displacement of fissures
- Loss of aeration
- Vascular & bronchial signs

INDIRECT SIGNS:

- Mediastinal & Hilar displacement
- Elevation of Hemidiphragm
- Compensatory hyperinflation

Patterns of Lung Collapse

- 1)Complete collapse of a lung
- 2)Lobar collapse

Atelectasis Right

Atelectasis Right

- Homogenous density right hemithorax
- Mediastinal shift to right
- Right hemithorax smaller
- Right heart and diaphragmatic silhouette are not identifiable

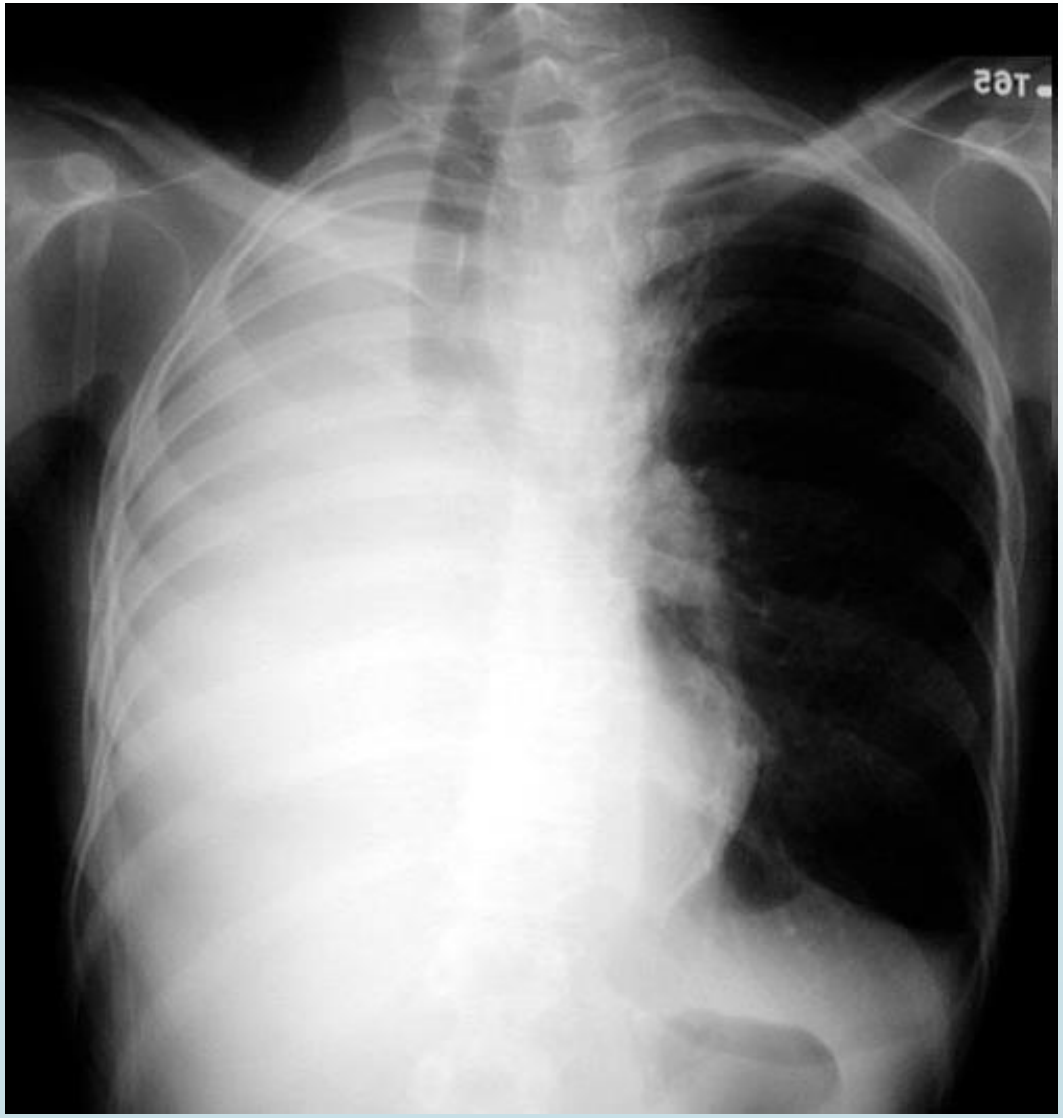

Atelectasis Left

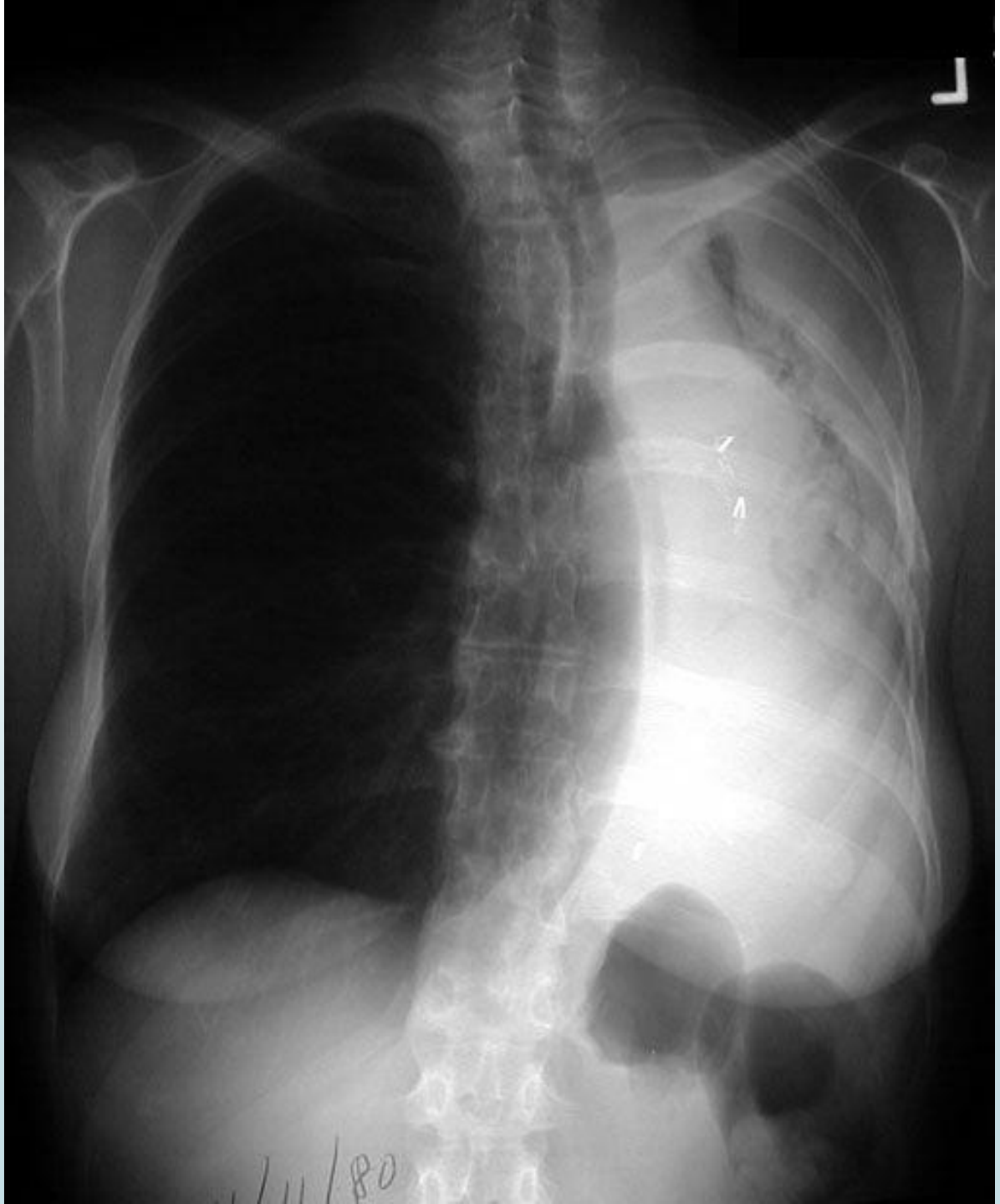

Collapse RUL

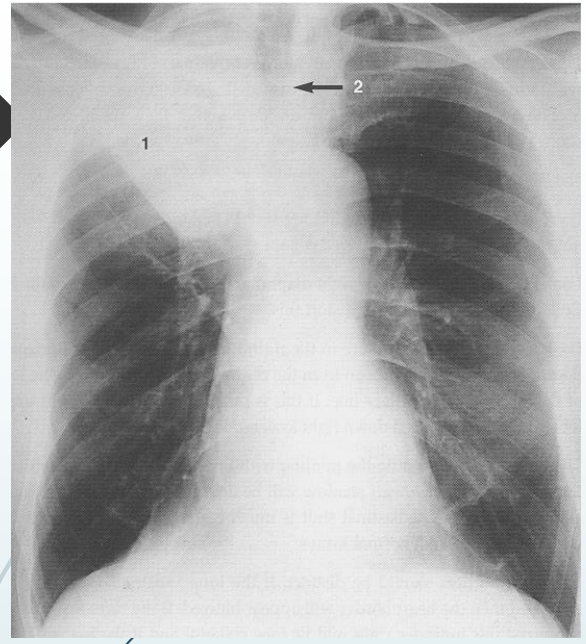

- Right upper lobe collapse: white-ness in the right upper zone(1).
- Elevated horizontal fissure & trachea is deviated to the right (2)
- The ribs over the area of whiteness are closer together than is normal.

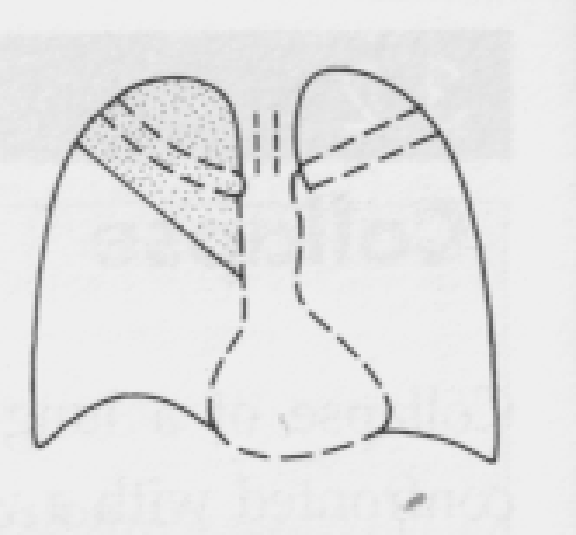

On the lateral film (above) the increased whiteness in the upper-most part of the chest may be seen.

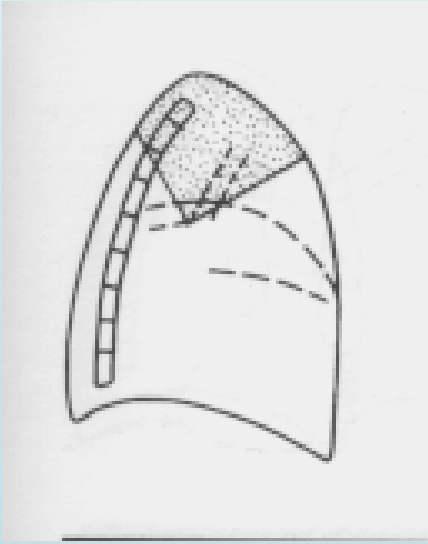

Right Upper Lobe Atelectasis

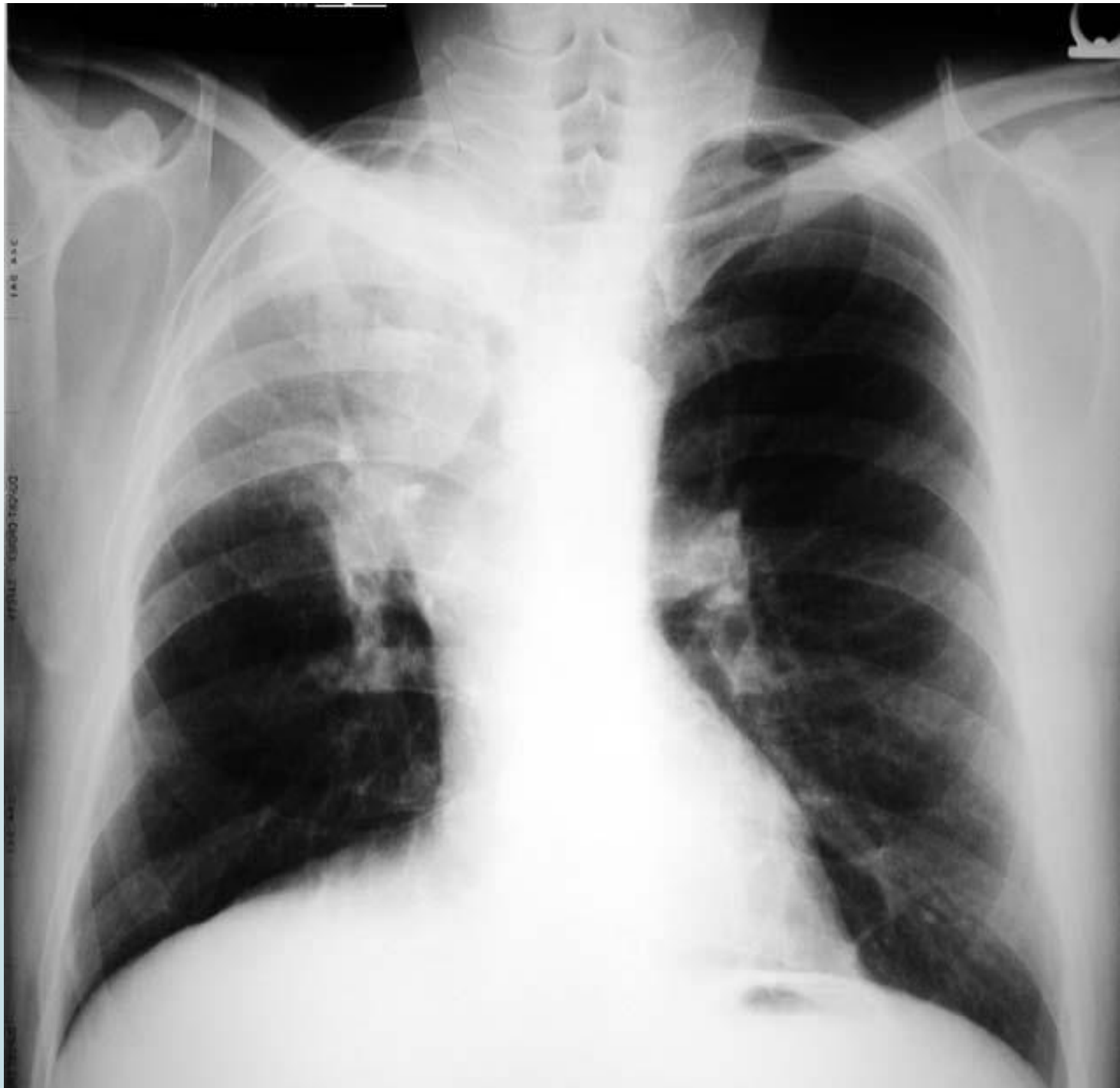

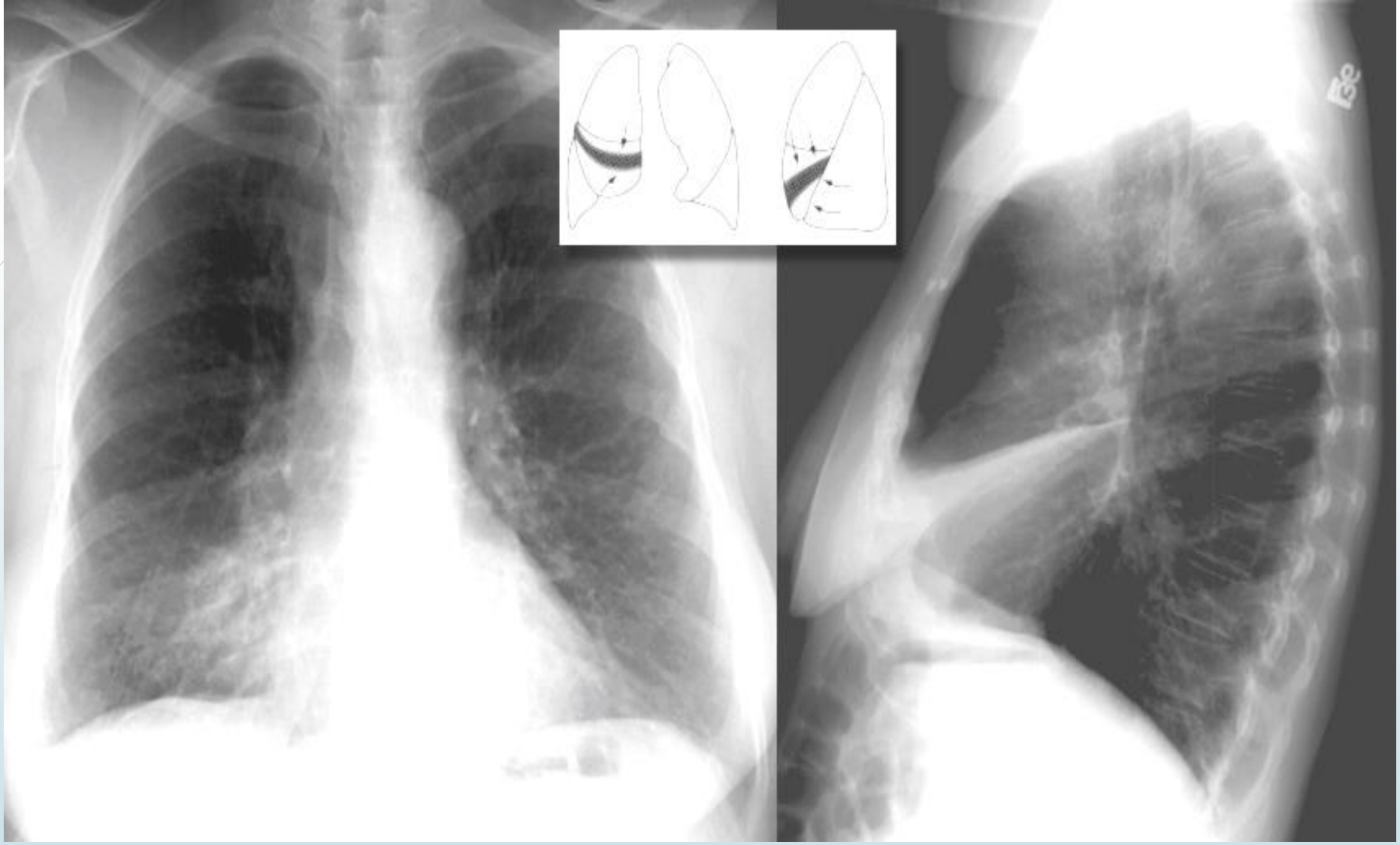

Right Middle Lobe Atelectasis

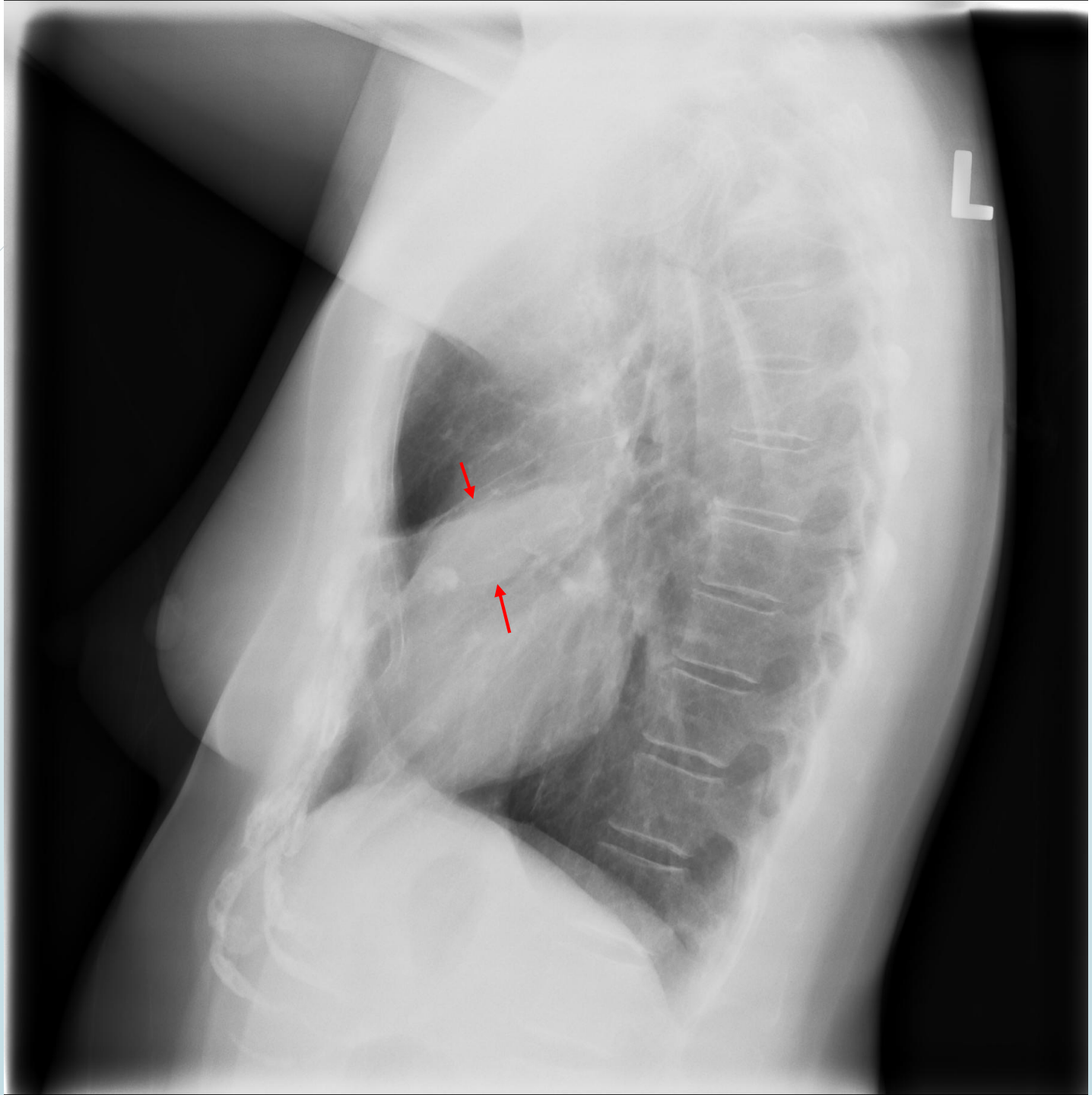

Right Middle Lobe Atelectasis

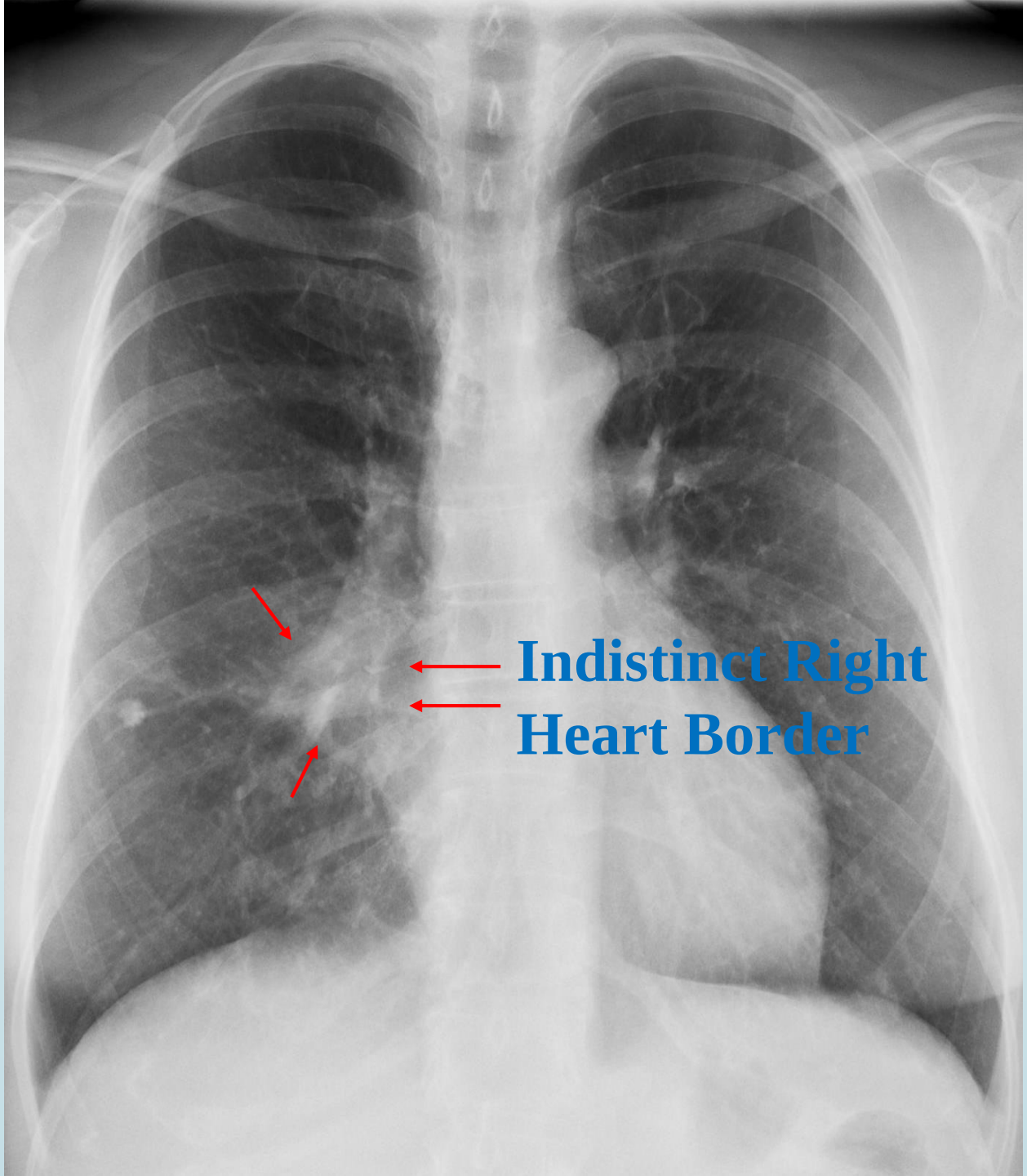
Indistinct Right
Heart Border

RLL Collapse

Collapse LUL

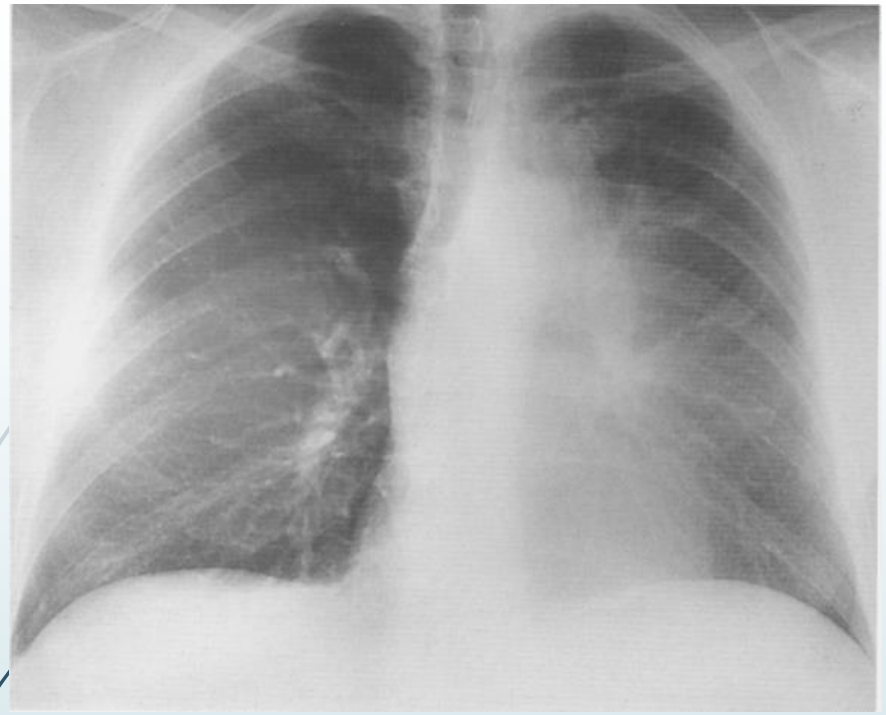

4. Left upper lobe collapse. This is difficult to spot. Remember that most of the left upper lobe lies in front of, as opposed to above, the left lower lobe. When it collapses it causes a haze to appear over the whole of the left lung field.

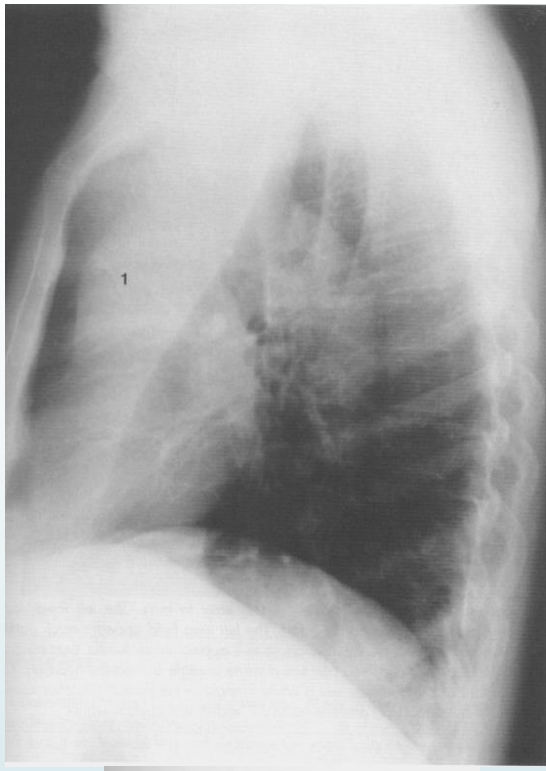

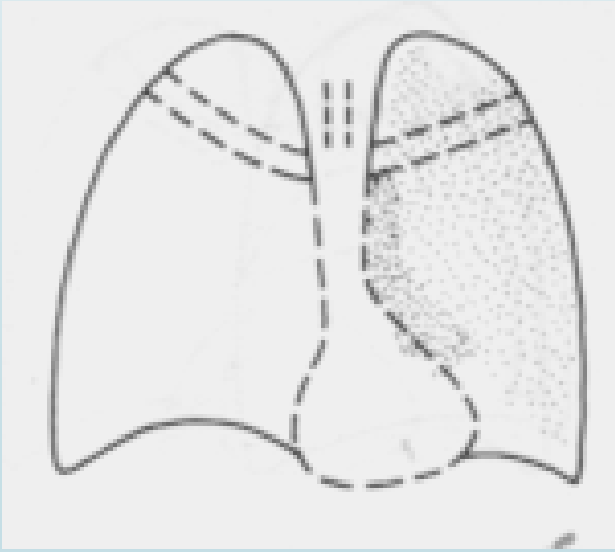

On the lateral film an area of whiteness can sometimes be seen of the very top of the lung fields (1).

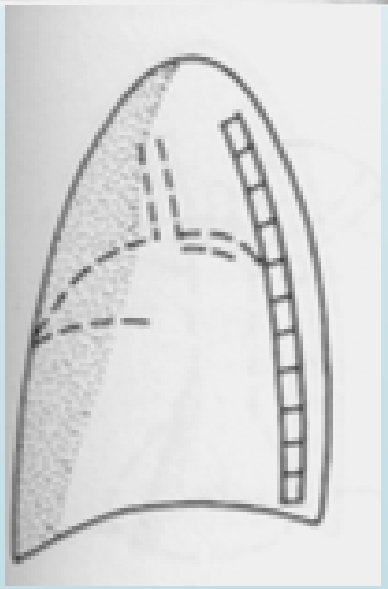

Atelectasis Left Lower Lobe

- Inhomogeneous cardiac density
- Left hilum pulled down
- Non-visualization of left diaphragm
- Triangular retrocardiac atelectatic LLL

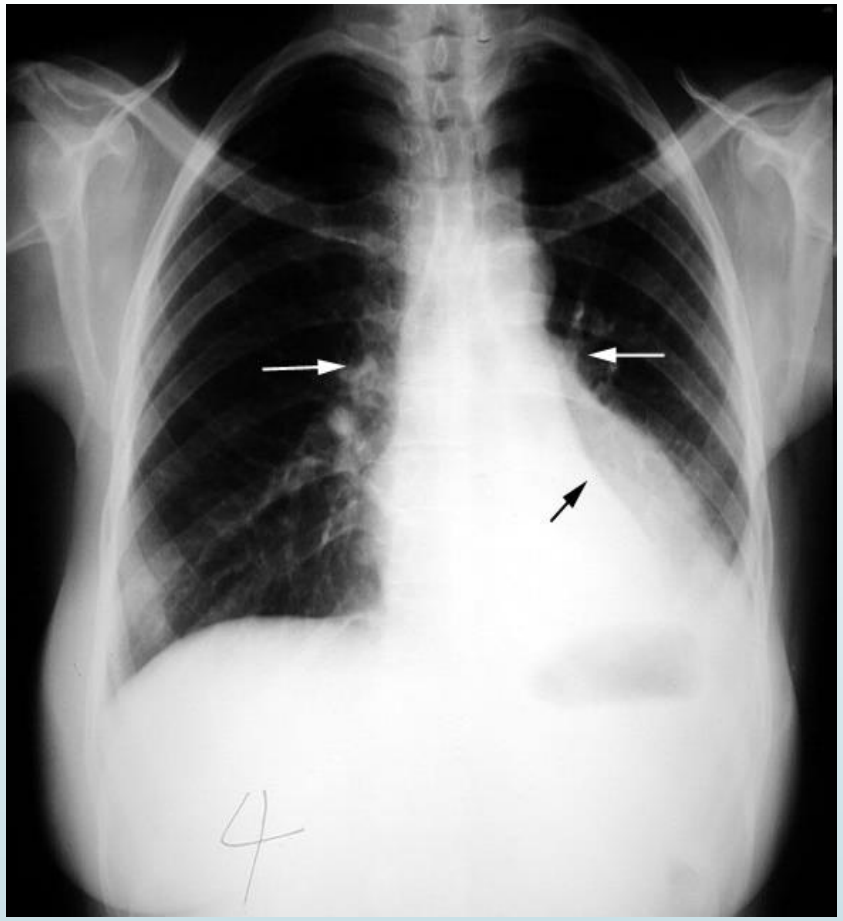

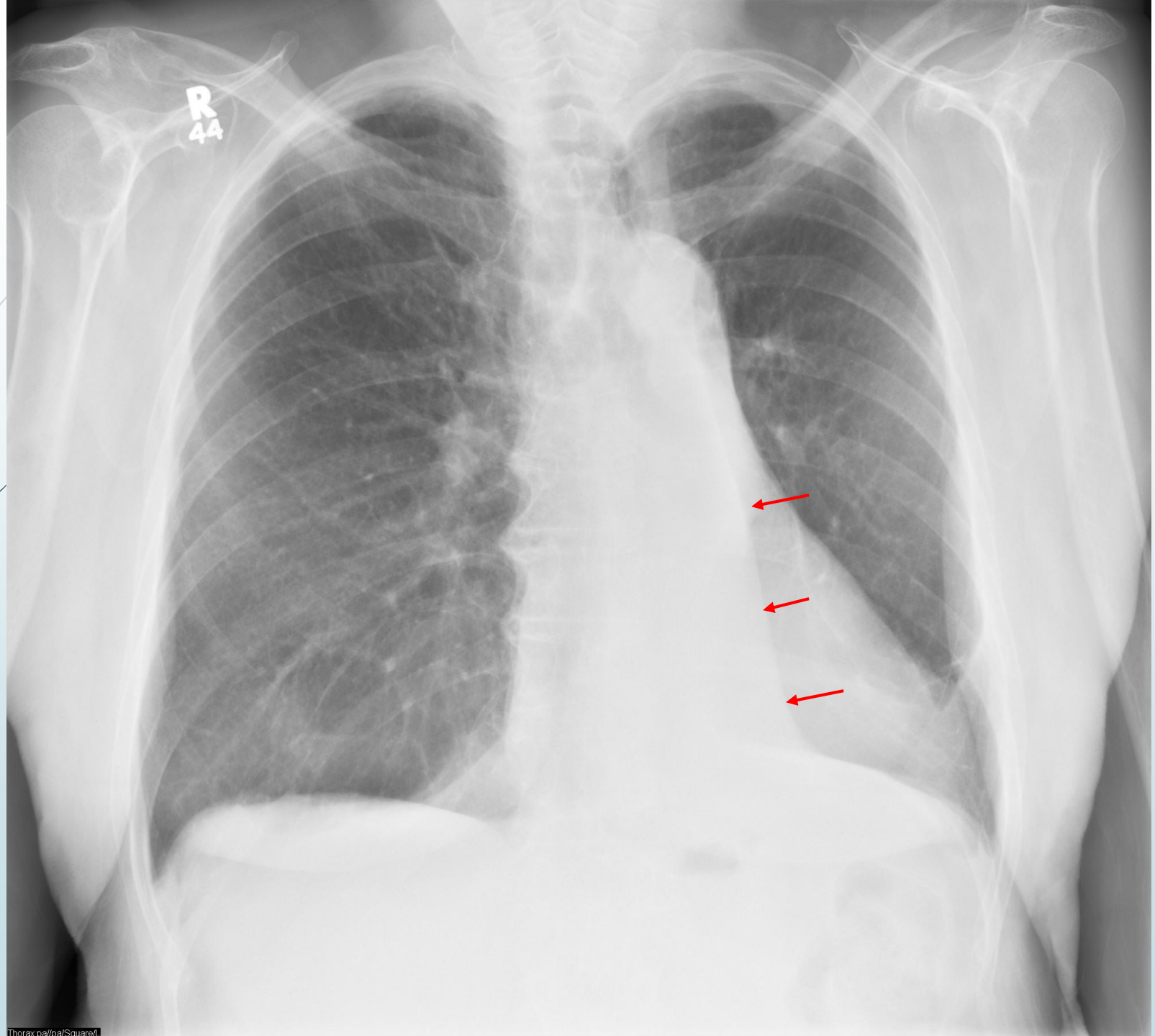
R
44
Thorax pa/oa/Square/

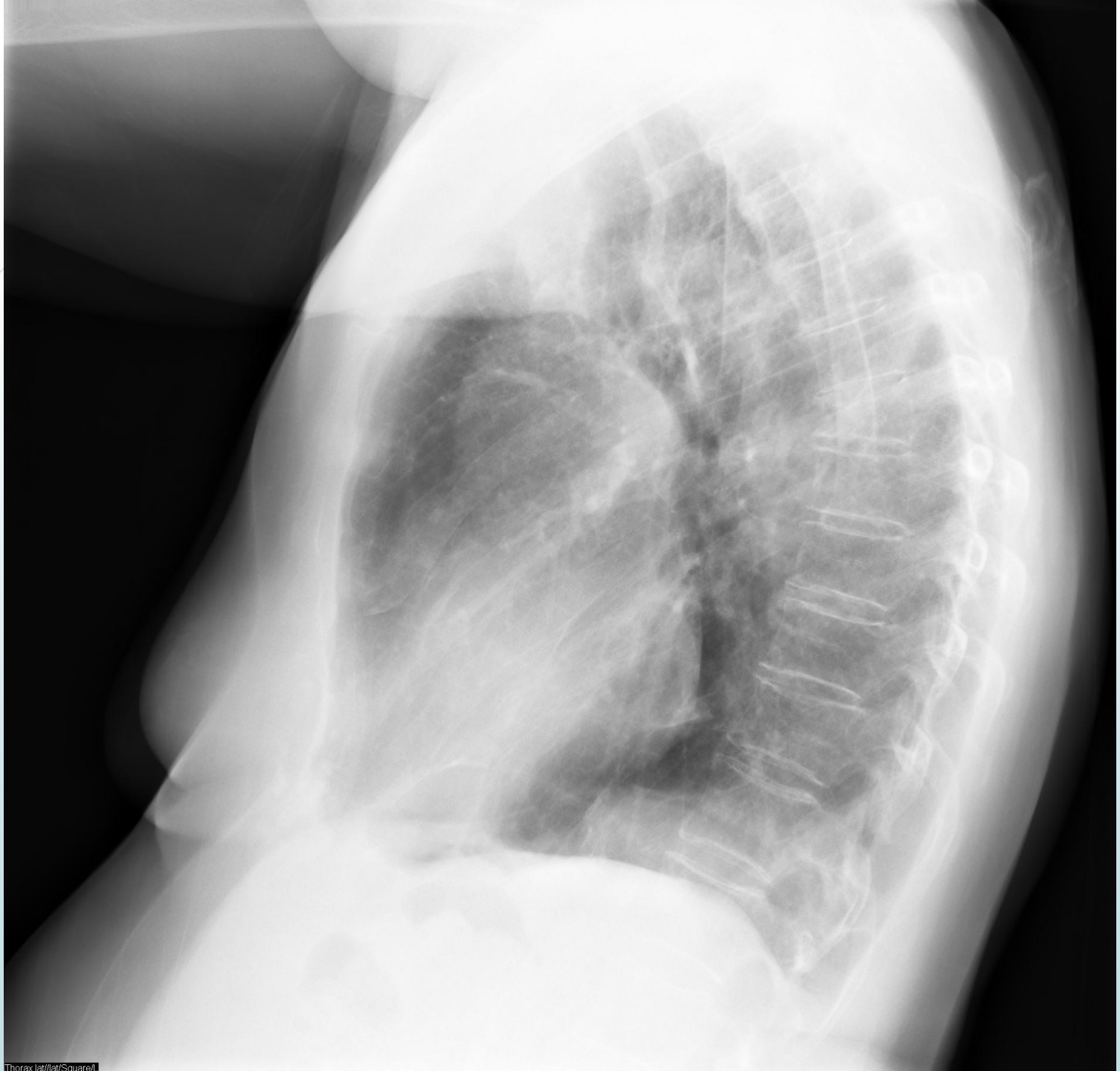
Thorax lat/lat/Square/l

Left lower lobe collapse

- Further investigations?

- Collapse secondary to central obstructing tumour

Diagnosis: LLL Collapse

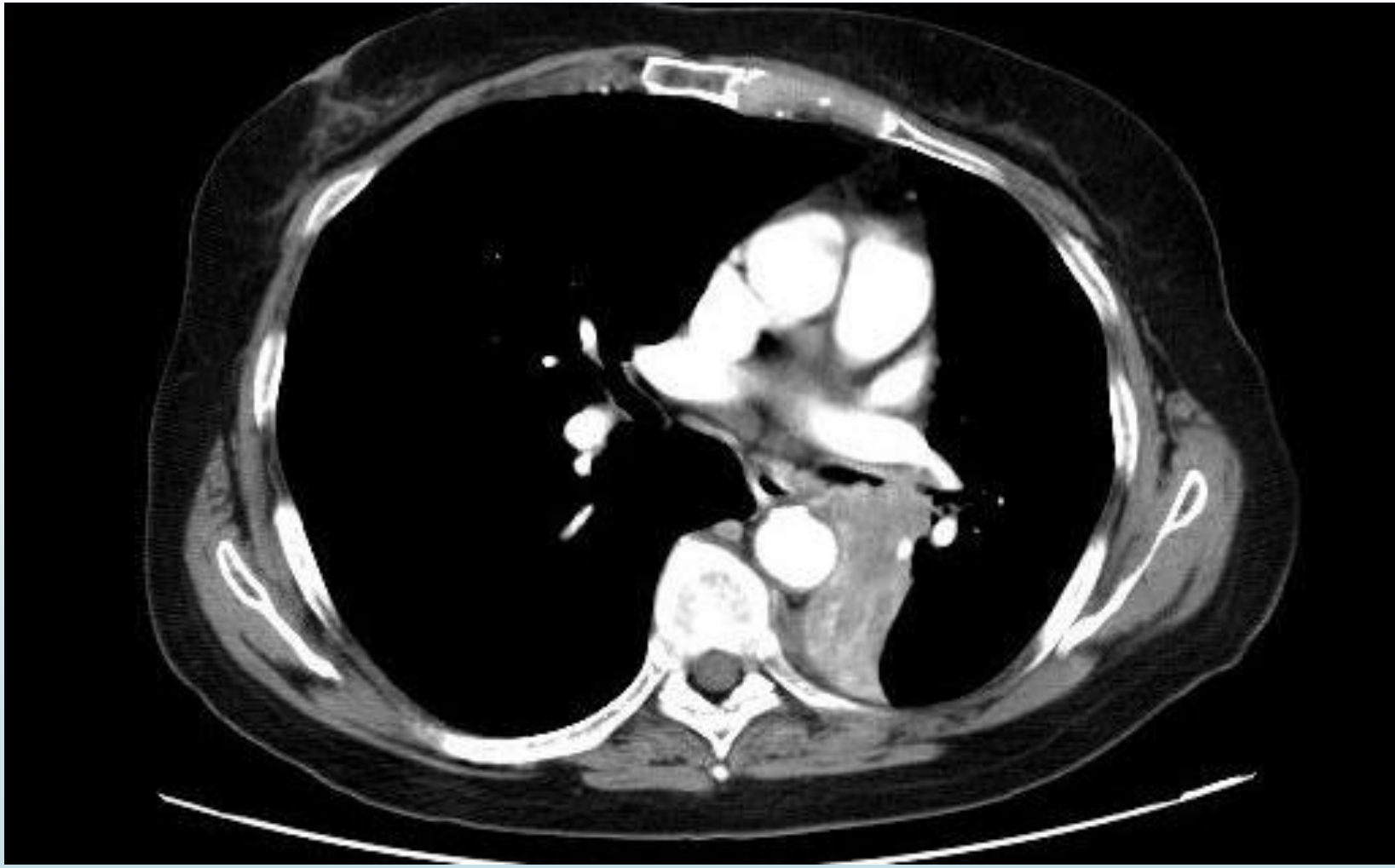

Atelectasis Left Lower Lobe

Collapse on USG

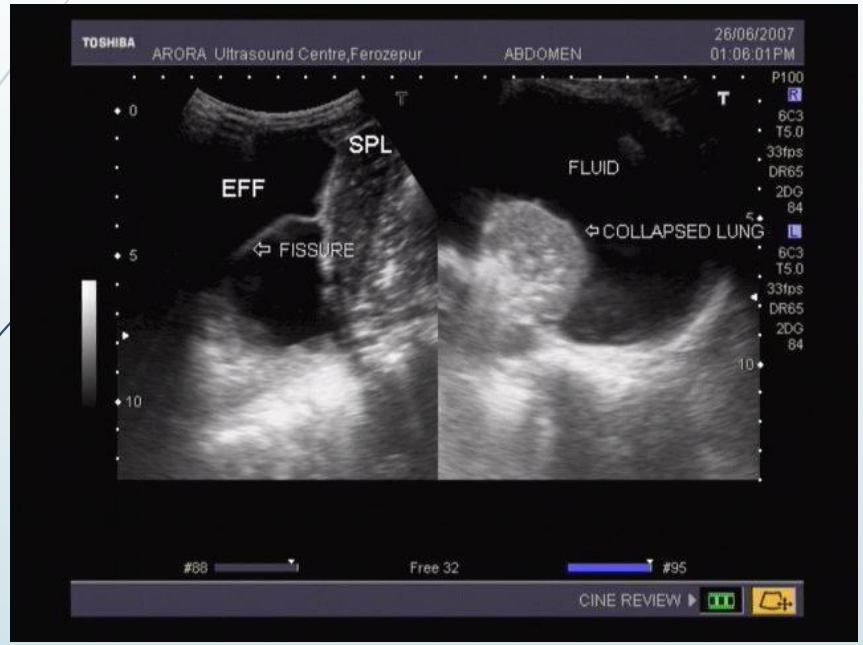

- Sonography of the chest was done in this patient. Images reveal a large, clear, hypoechoic fluid collection in the left pleural space. The left lung has collapsed into a small mass of tissue compressed by the effusion. A small fibrotic band is seen traversing the fluid. These ultrasound images are diagnostic of pleural effusion

Pulmonary fibrosis

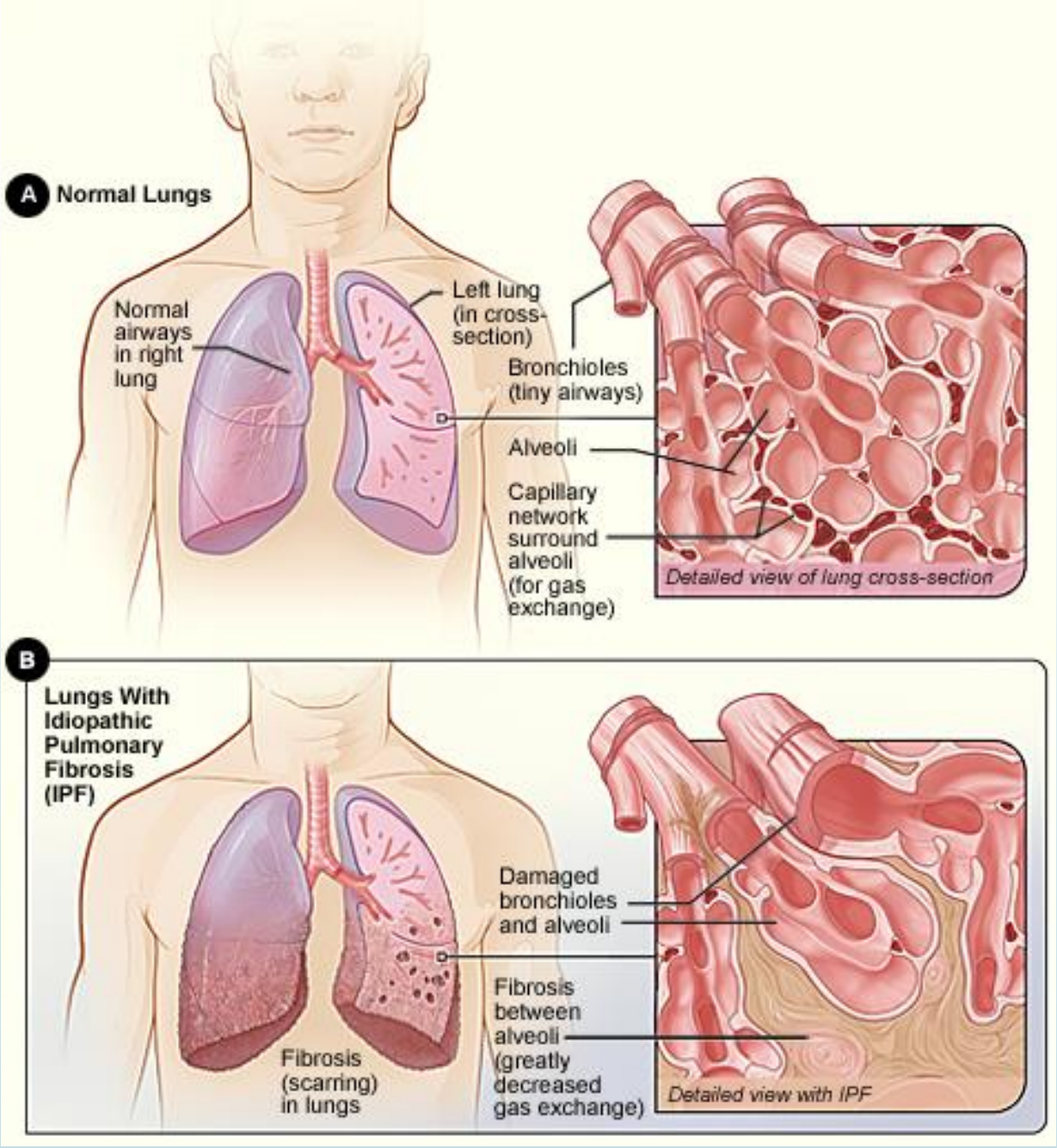

Fibrosis

- Diffuse haziness
- Apical cap thickening
- Blunting of costophrenic angle
- No shift of fluid in lateral decubitus
- Loss of lung volume
- Lines not corresponding to fissures

Pleural Fibrosis

- Small right hemithorax
- Diffuse haziness
- Tracheal shift to right
- Blunted costophrenic angle
- Lines not corresponding to fissures

Pleural Effusion

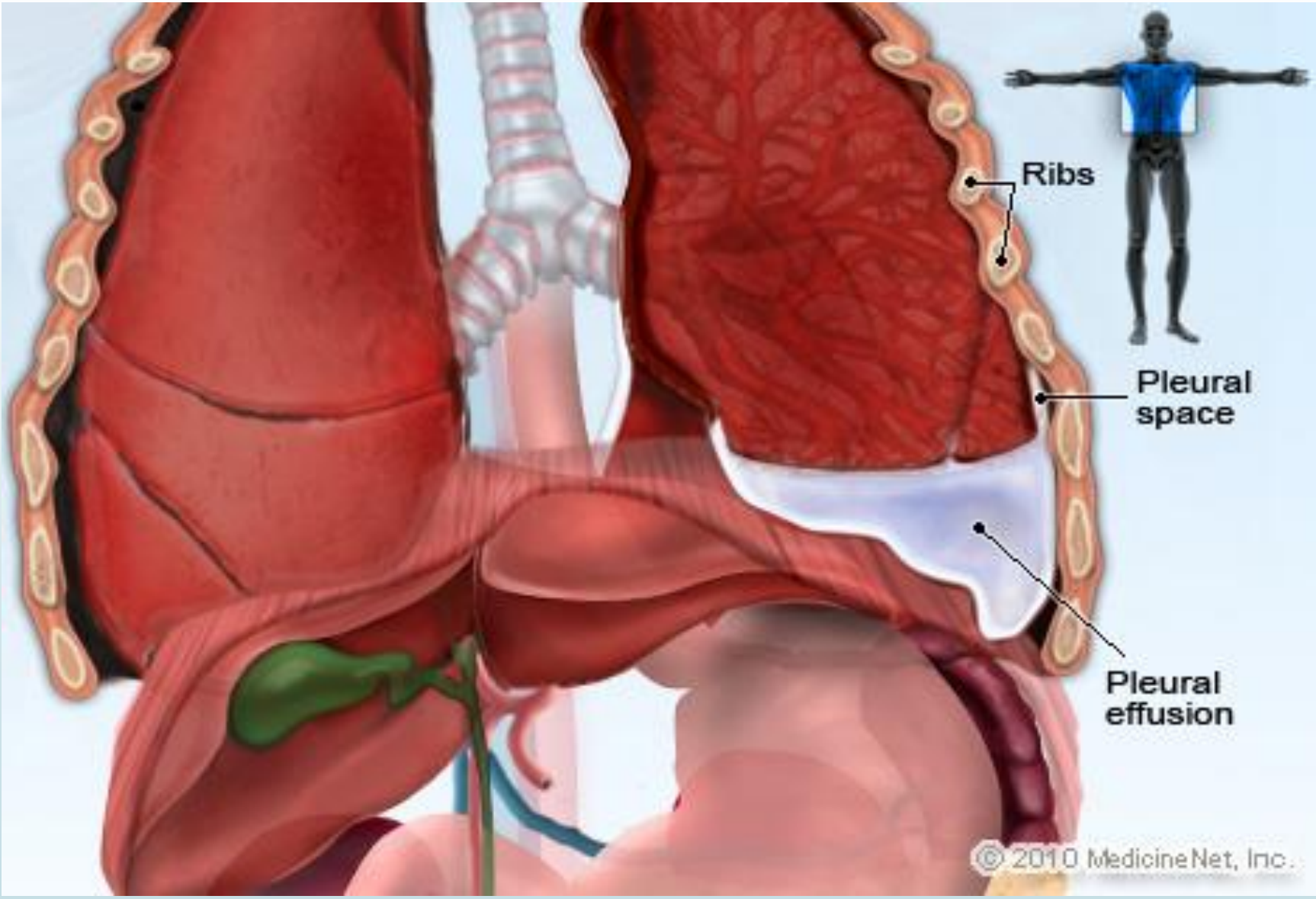

Pleural Effusion

- Fluid accumulates in the pleural space.
- **Radiological criteria** are:
- Increased Density
- In dependent portion
  - Costophrenic angle in PA view
  - Along sides in lateral decubitus position
  - Along posteriorly in supine position, giving diffuse haziness on the side of effusion
- Blunting of costophrenic angle
- Lack of identifiable diaphragm (silhouette sign principle).

Pleural Effusion

- Homogenous density
- Meniscus maximum in axilla
- Loss of cardiophrenic angle
- Loss of diaphragmatic and right cardiac silhouette

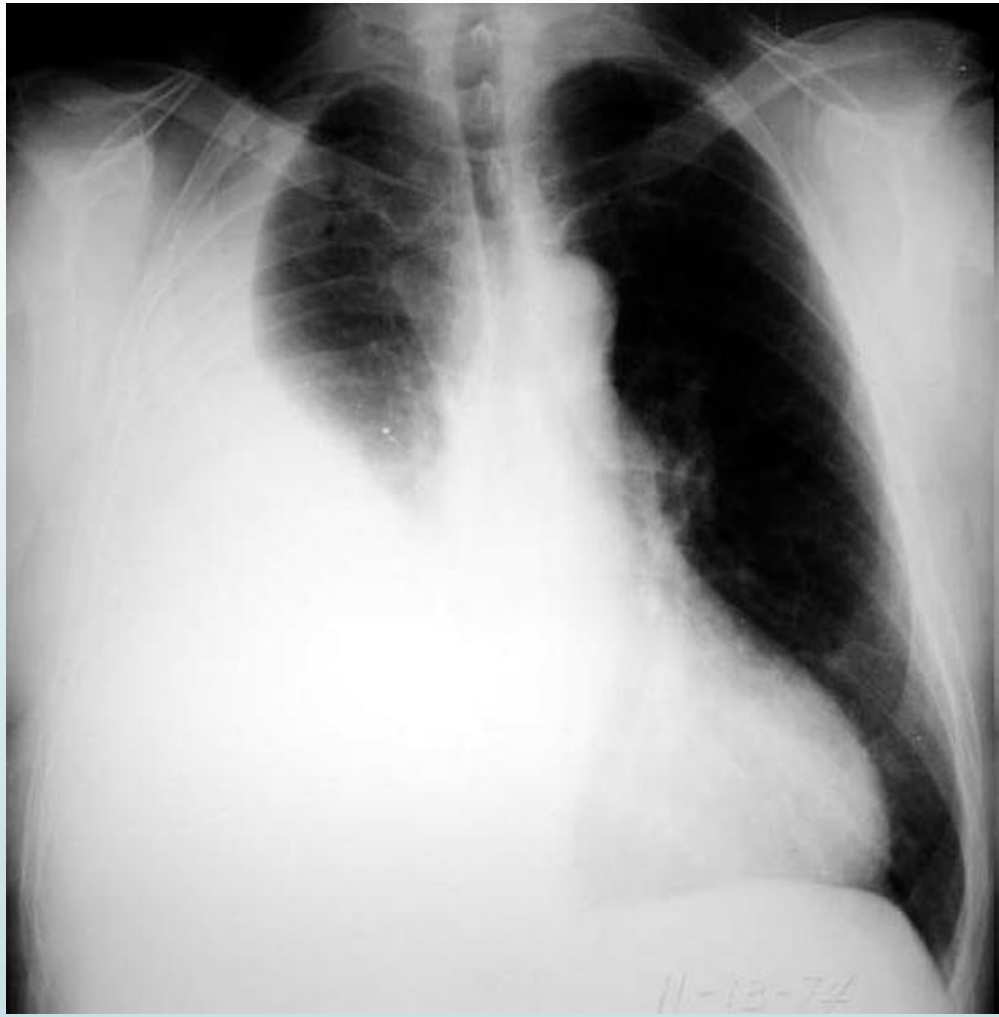

Massive Pleural Effusion

- Massive
- Shift of mediastinum

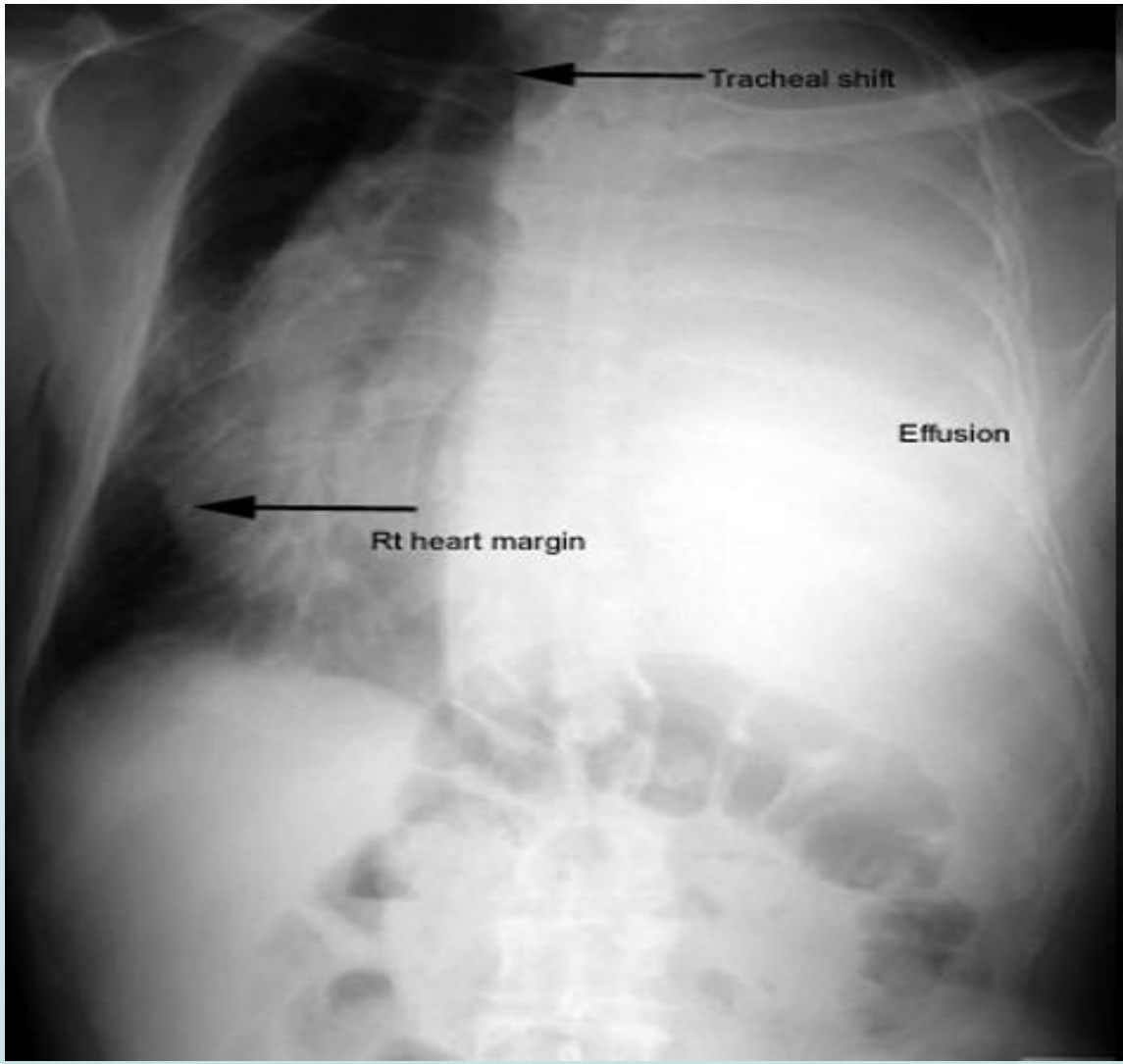

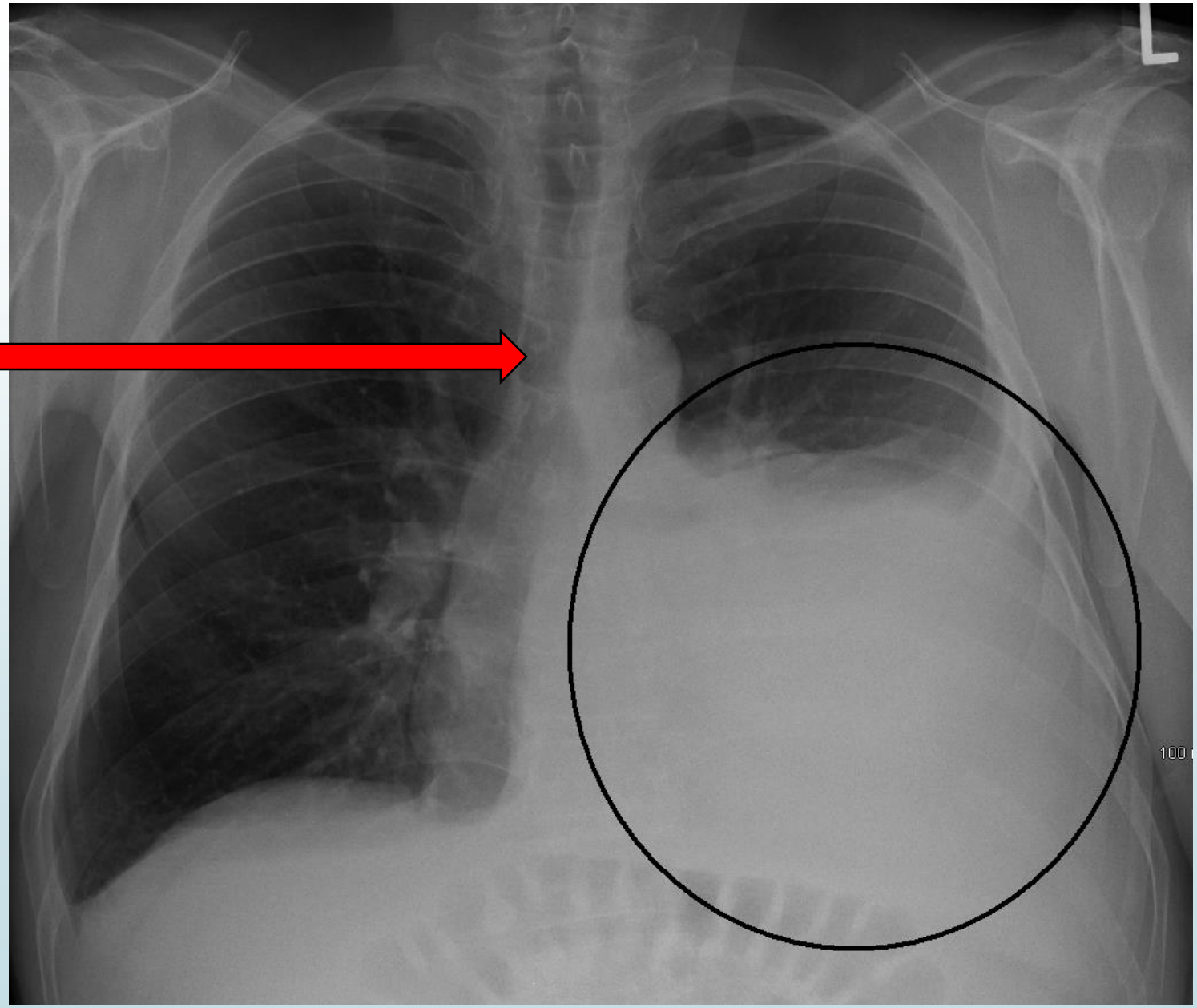
L

Pleural Effusion

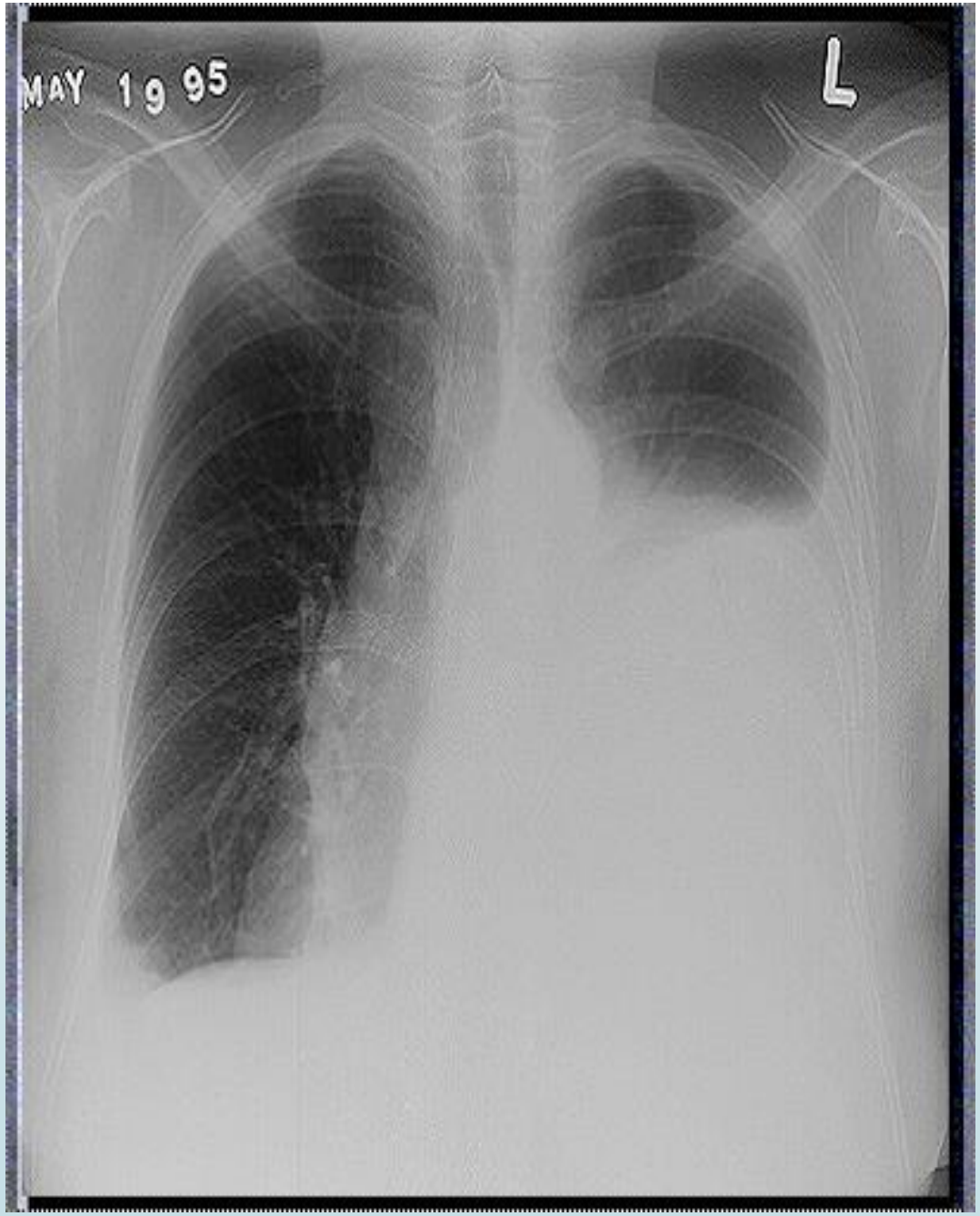

Small Pleural Effusion

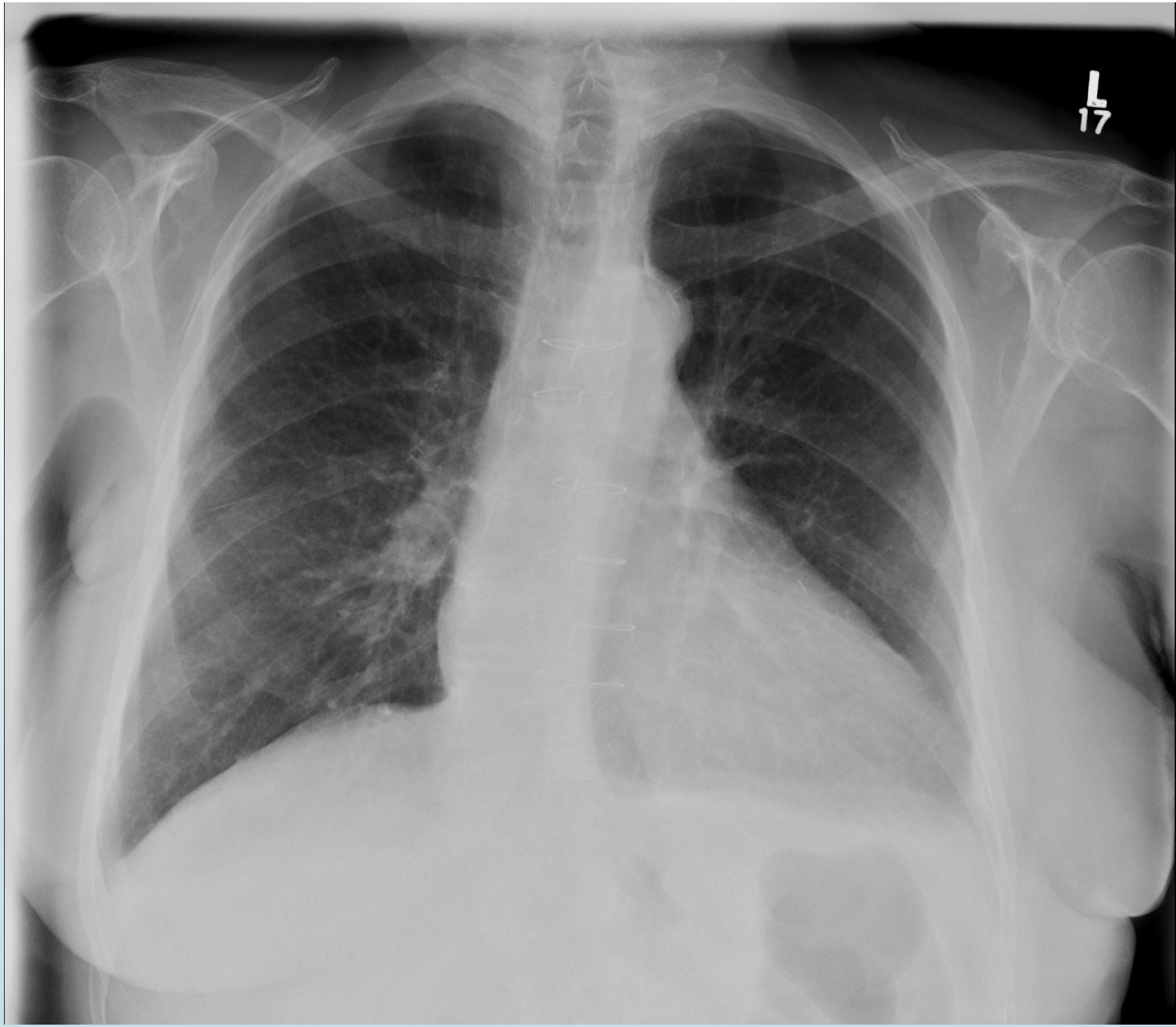

Small Pleural Effusion

Blunted posterior costophrenic sulcus

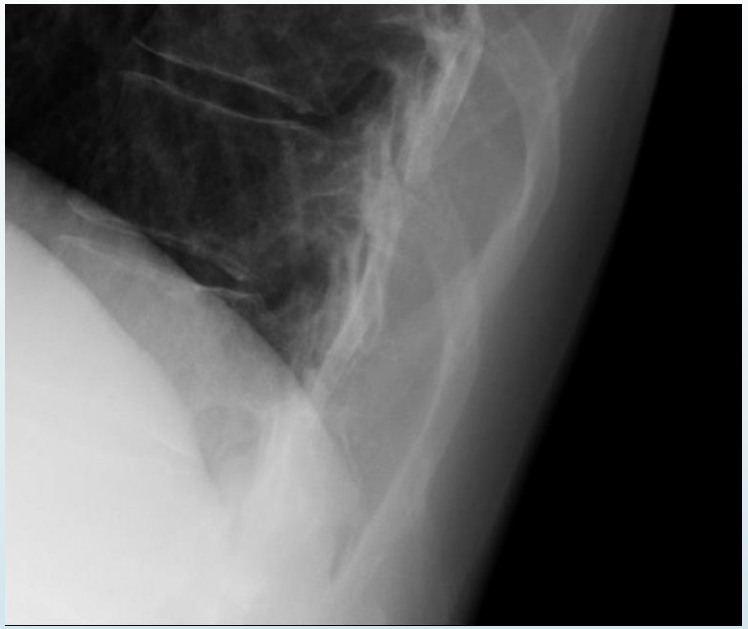

Normal:
Sharp Angles

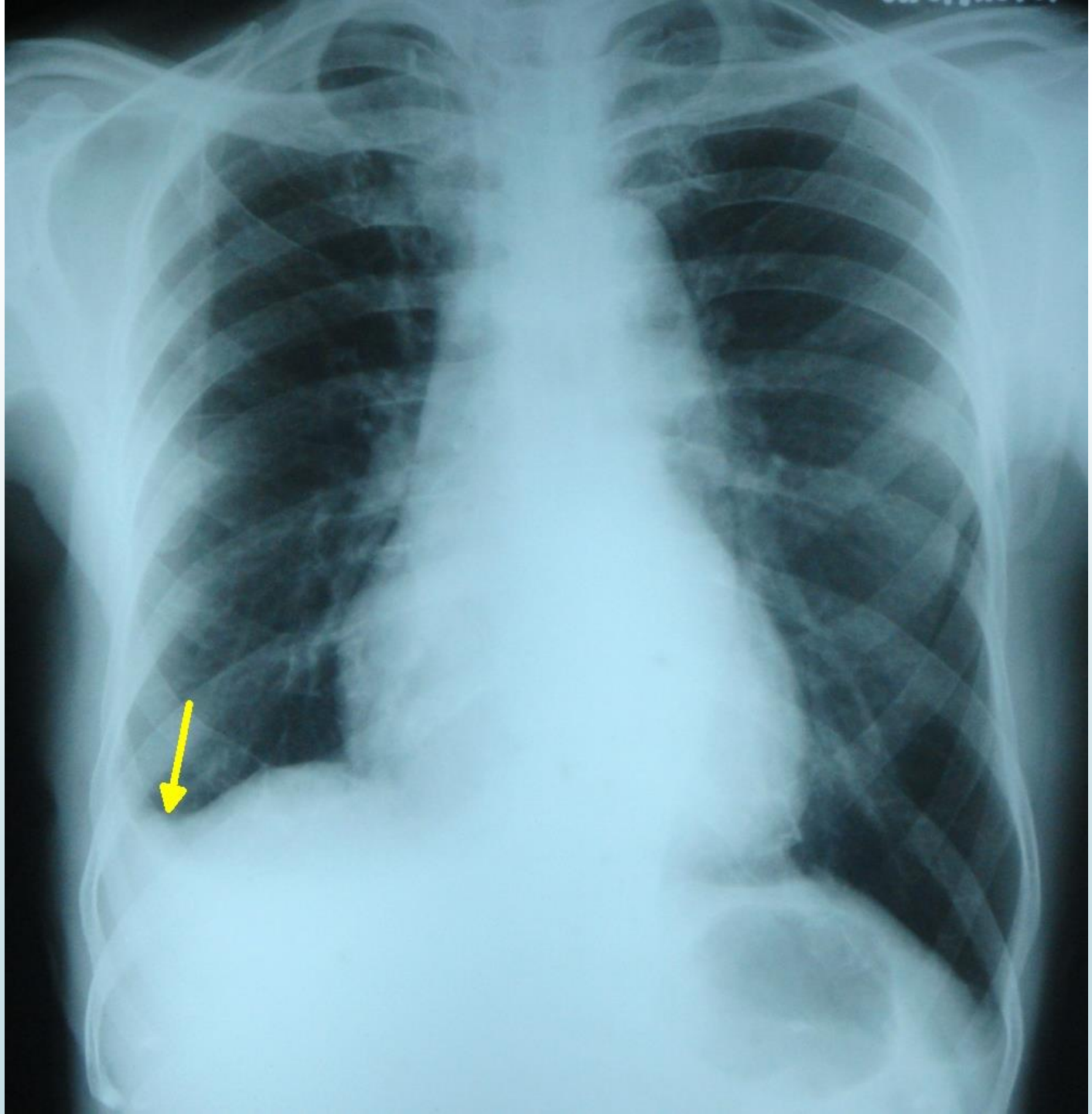

Loculated Pleural Effusion

- Homogenous density
- Loculated
- Loss of cardiophrenic angle
- Loss of lateral portion of diaphragmatic silh ouette

Loculated Pleural Effusion

A **subpulmonic effusion** is excess fluid that collects at the base of the lung, in the space between the pleura and diaphragm. The peak of the pseudo-diaphragm will lie lateral to the normal position. When located on the left, an increased distance may be seen between the pseudo-diaphragm and the gastric bubble.

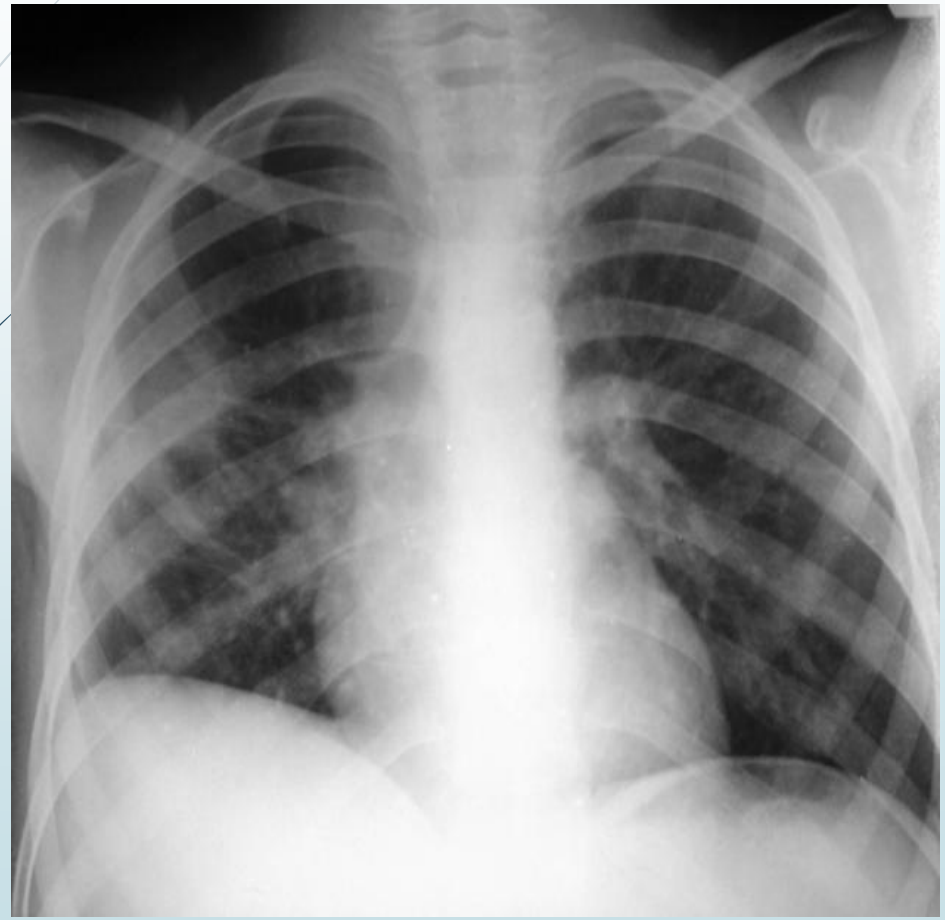

Lateralization of the diaphragm apex at the right side compatible with right sided subpulmonic effusion.

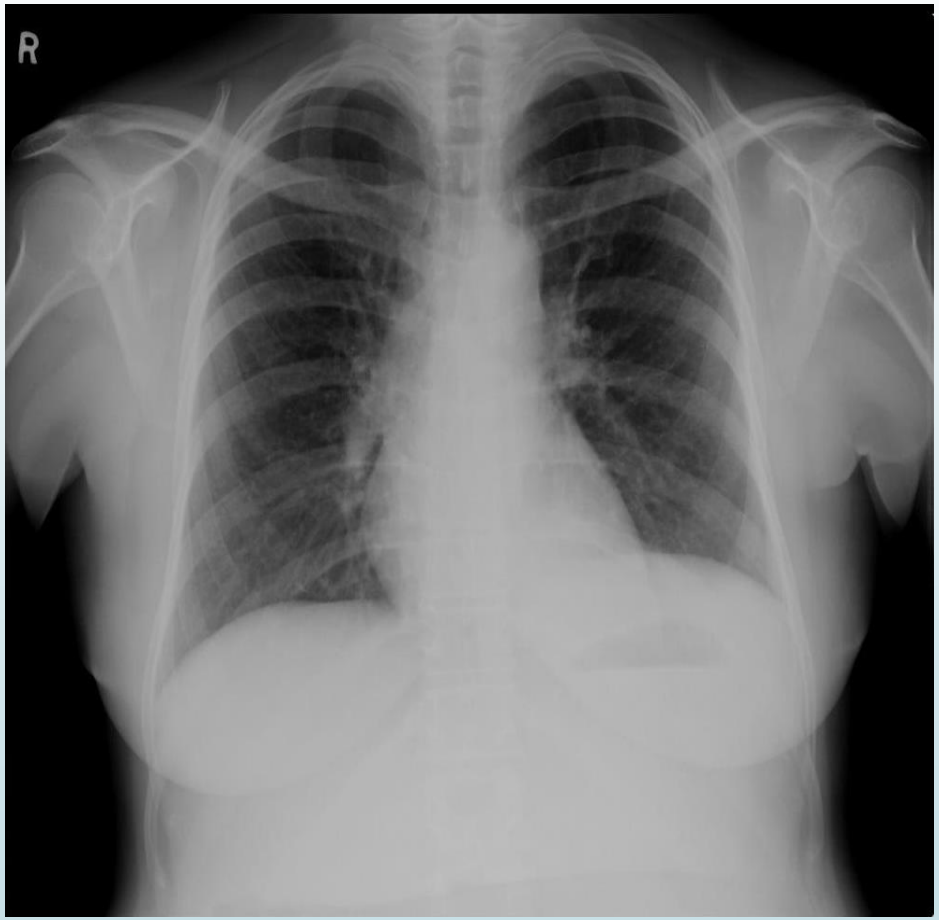

The left dome of diaphragm is higher than right with increased distance of diaphragmatic outline to the fundal air bubble of stomach, suggestive of a subpulmonic pleural effusion.

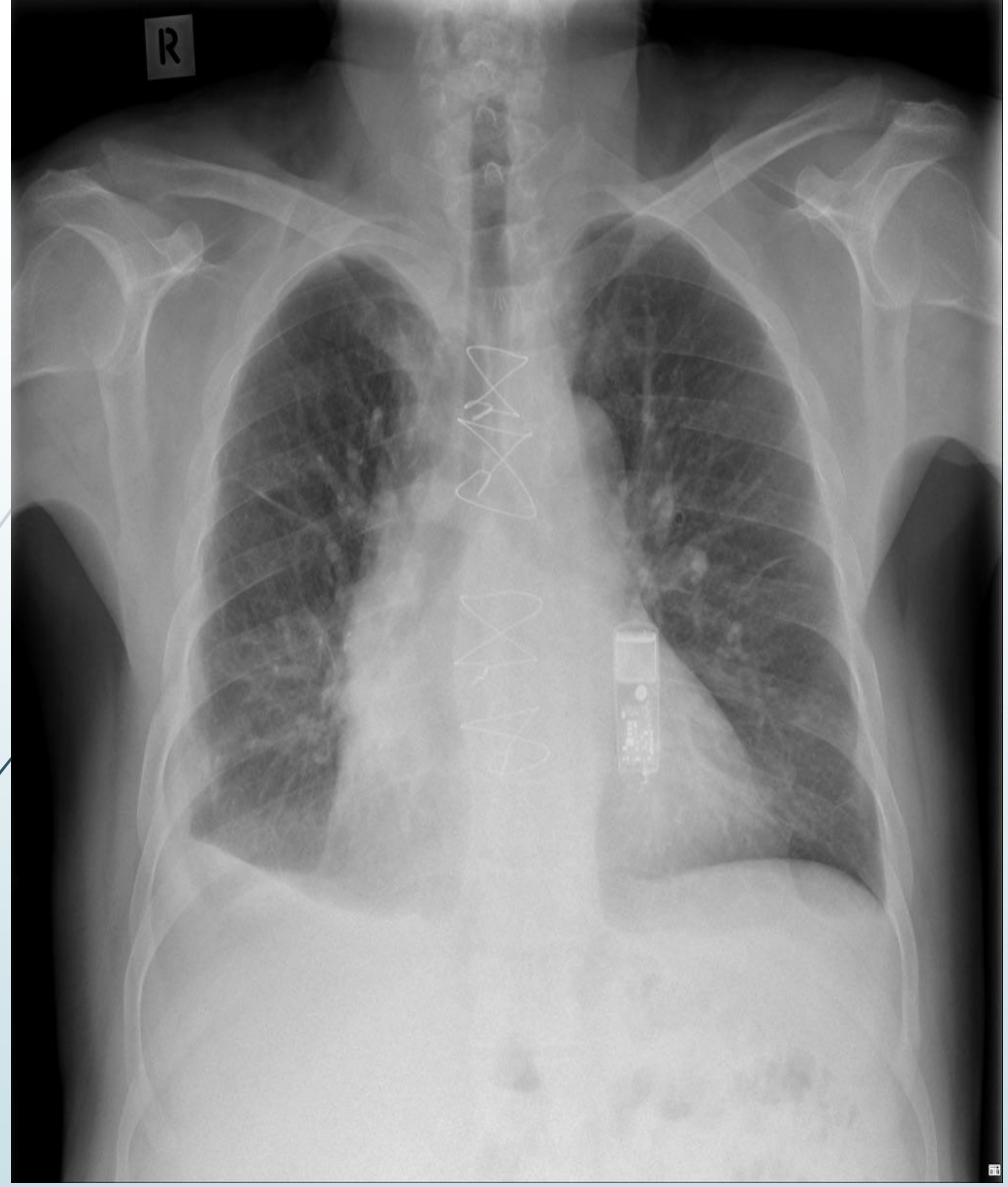

There is a moderate-sized right basal and right subpulmonic pleural effusion. Sternotomy wires and loop recorder noted. Moderate cardiomegaly.

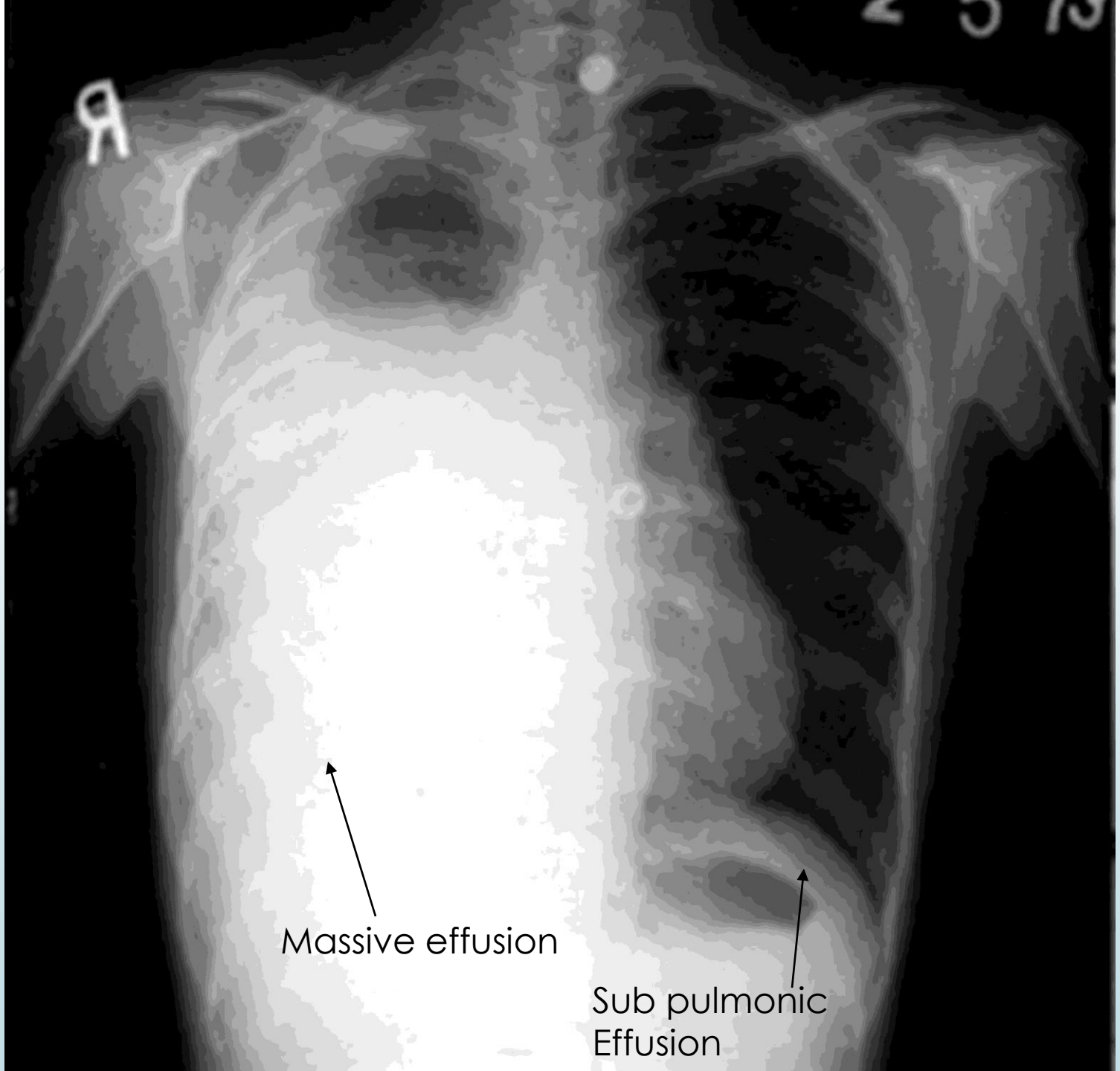
Massive effusion
Sub pulmonic
Effusion

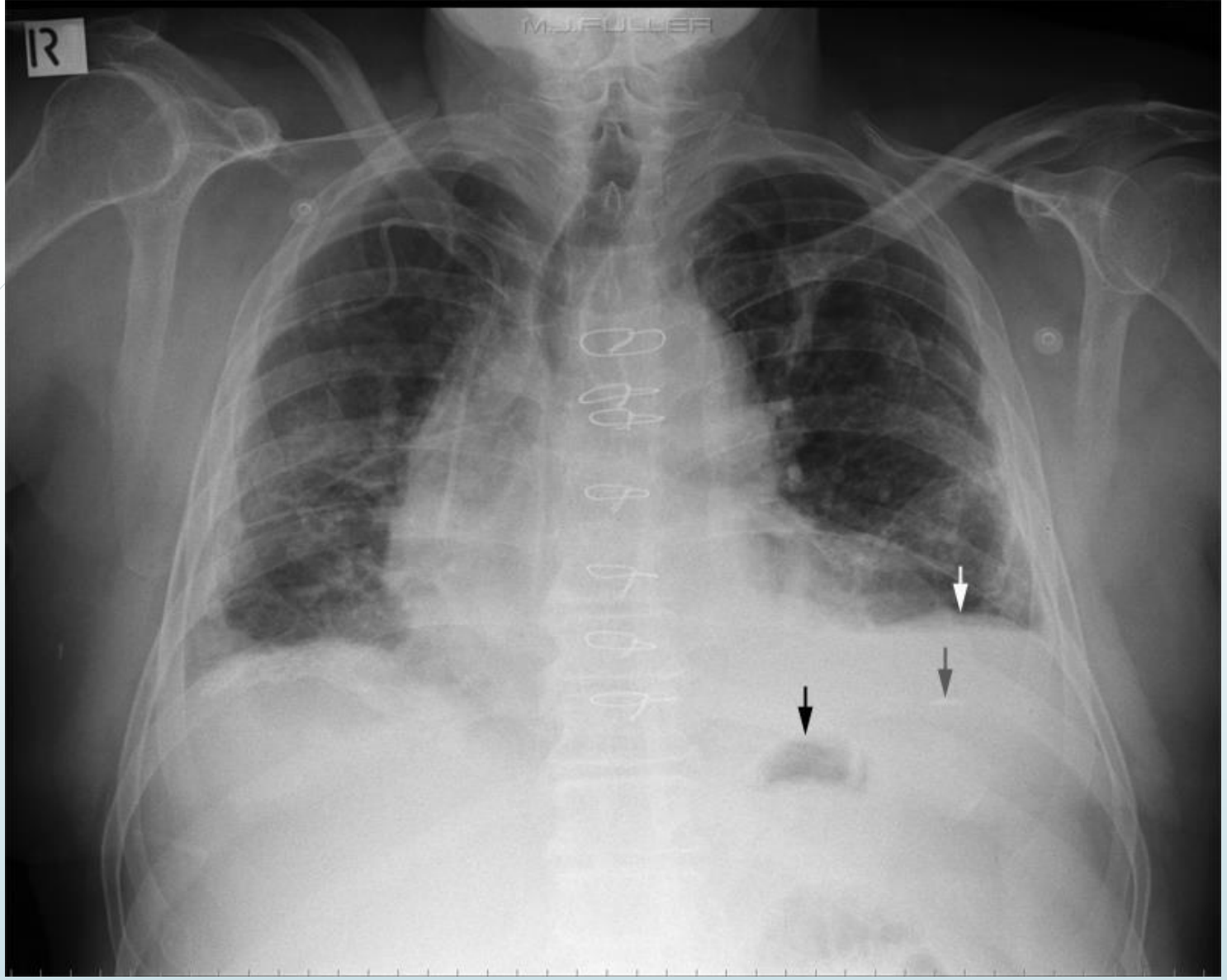

This is a PA chest image on the same patient taken after cardiac surgery. Note the increased distance between the fundus of the stomach (black arrow) and what appears to be the diaphragm (white arrow). The diaphragmatic plaque is marked by the grey arrow.

Pneumothorax

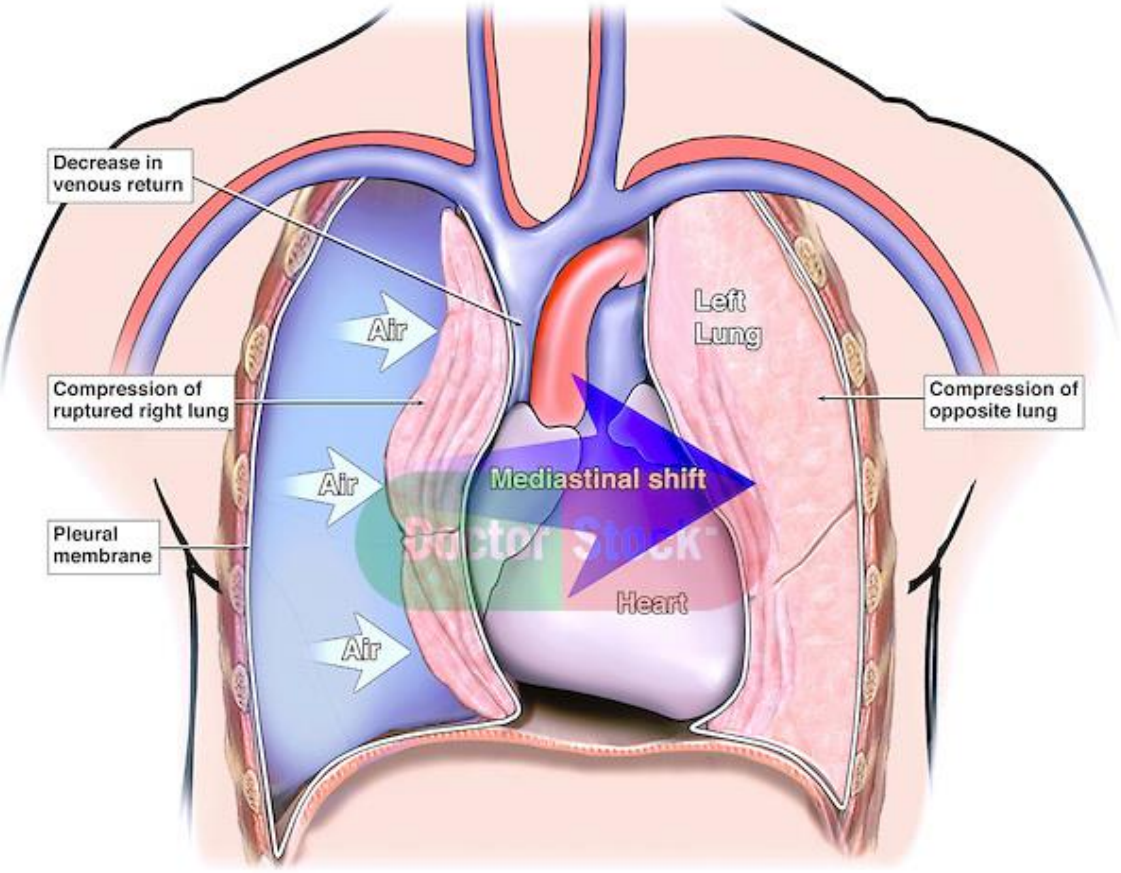

In a tension pneumothorax, air from a ruptured lung enters the pleural cavity without a means of escape. As air pressure builds up, the affected lung is compressed and all of the mediastinal tissues are displaced to the opposite side of the chest.

Causes of Pneumothorax

- Spontaneous
- Iatrogenic/trauma,
- Obstructive lung disease, e.g. asthma, COPD
- Infection, e.g. pneumonia, tuberculosis Cystic fibrosis
- Connective Tissue Disorders, e.g. Marfan's, Ehlers-Danlos

Pneumothorax

- **Air (black) in pleural space.** With No lung markings
- Recognition of atelectatic lung (lung margin).
- **Shift of mediastinum** to the opposite side.
- **Larger hemithorax.**
- **Opposite lung** - vascular markings prominent.

Pneumothorax

- No vascular markings on right
- No shift of mediastinum to left
- Atelectatic right lung
- Increased haziness on left
- Small fluid level near costophrenic angle: Hydro pneumothorax

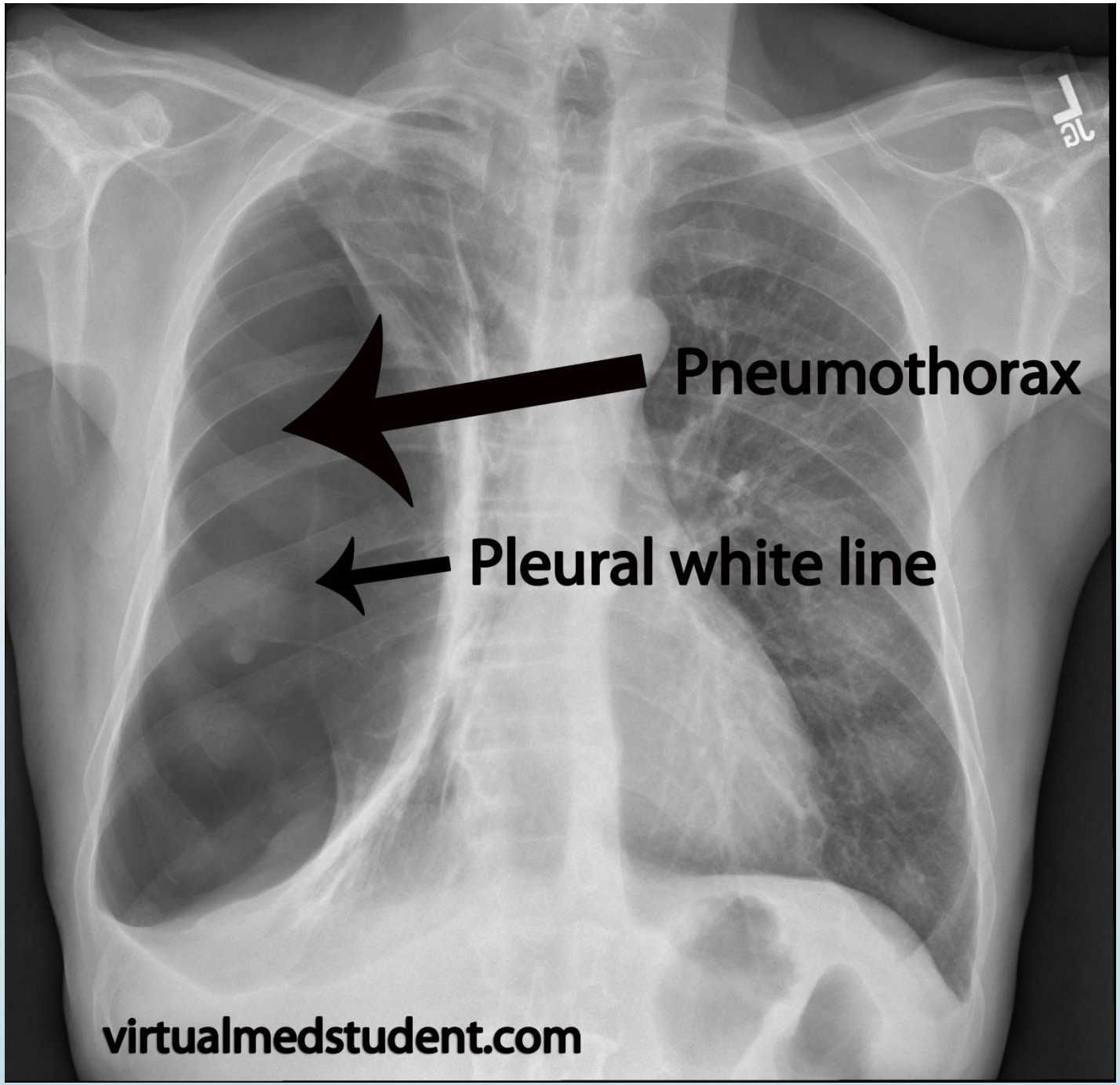
Pneumothorax
Pleural white line
virtualmedstudent.com

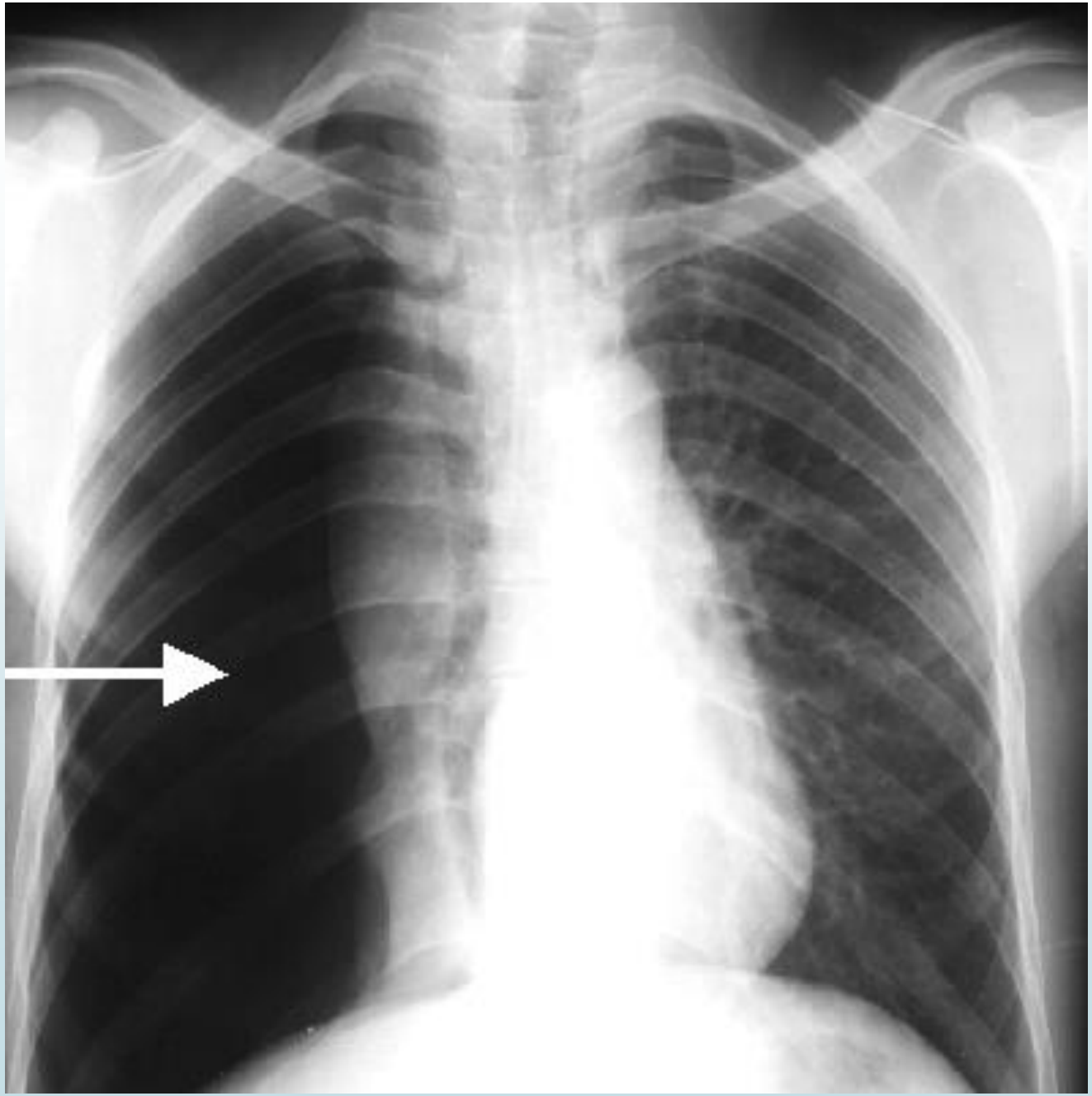

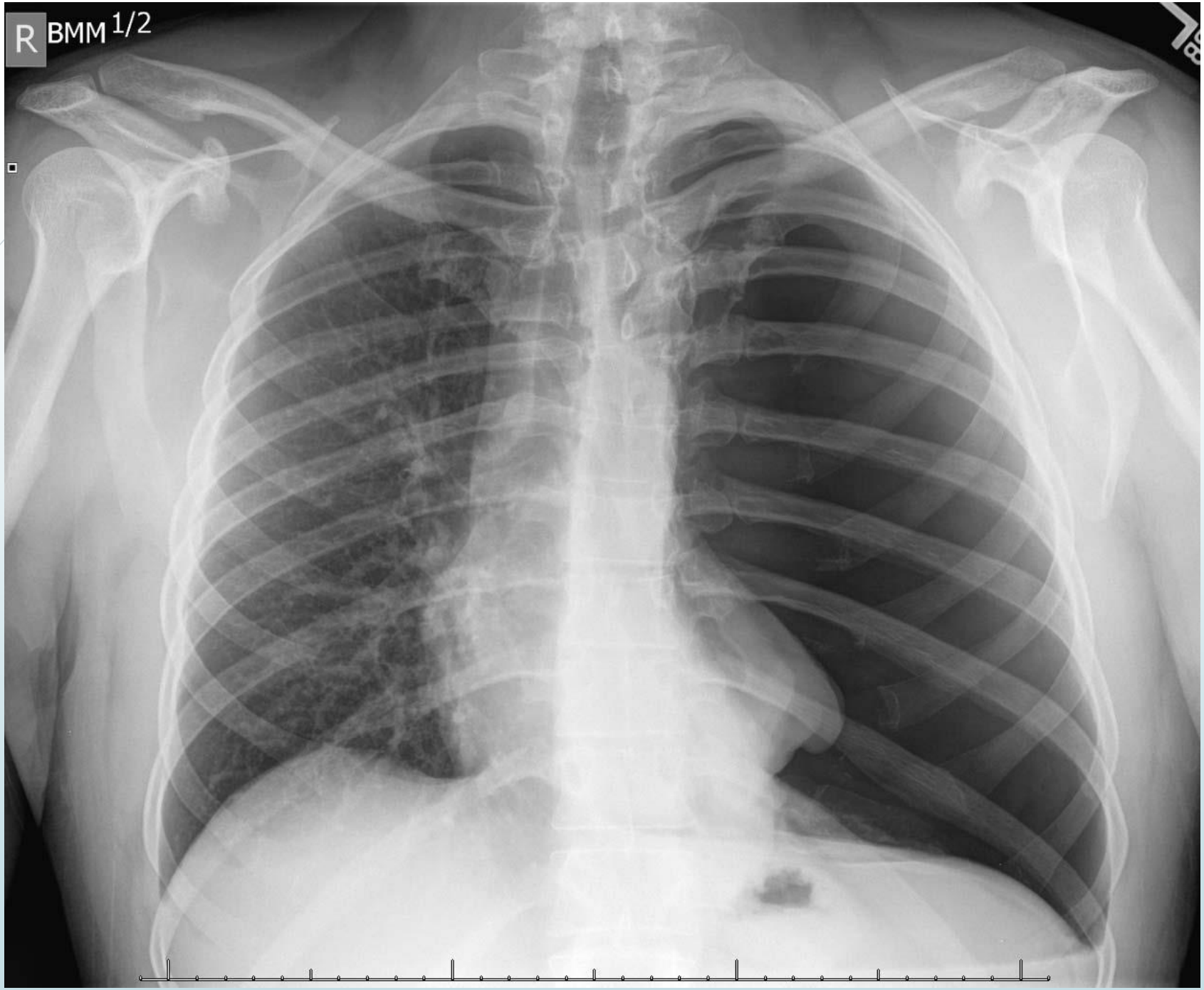
R
BMM 1/2

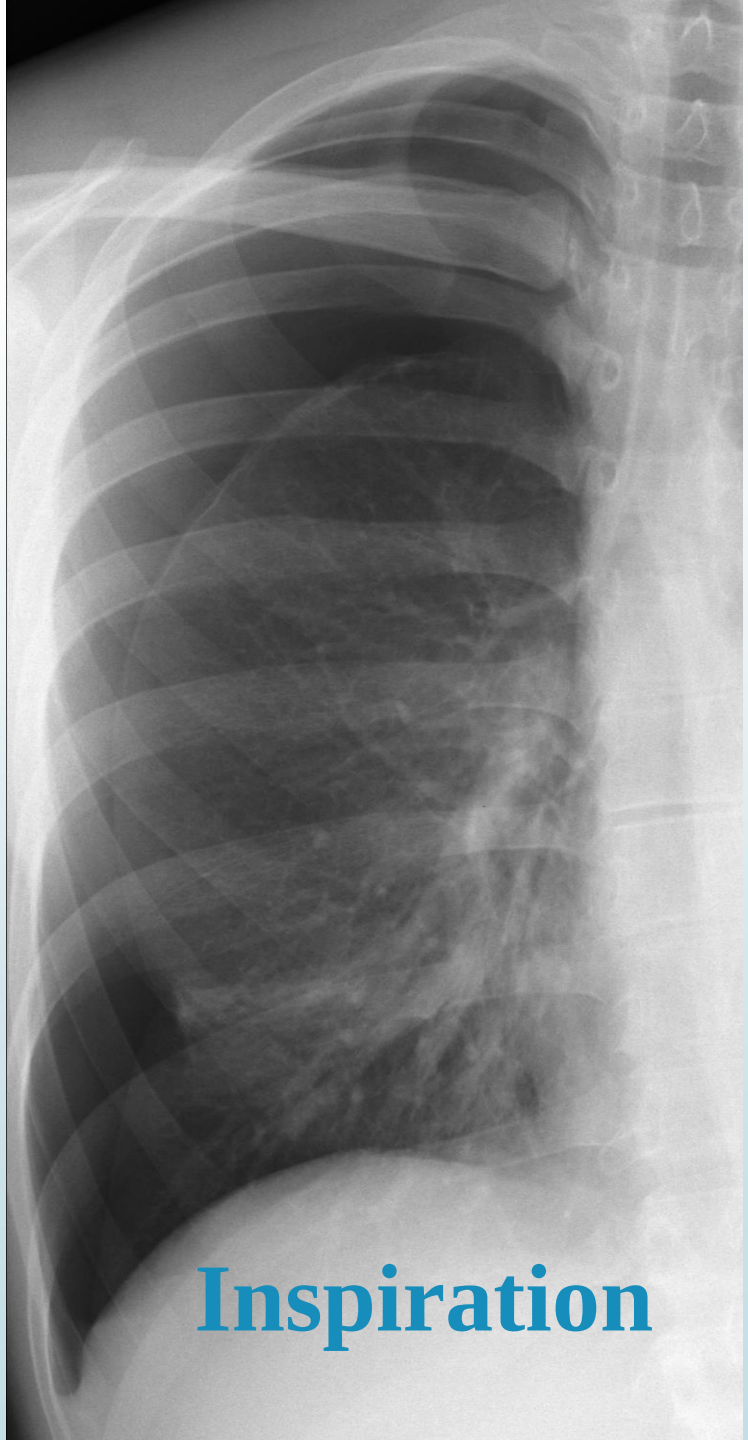
Inspiration

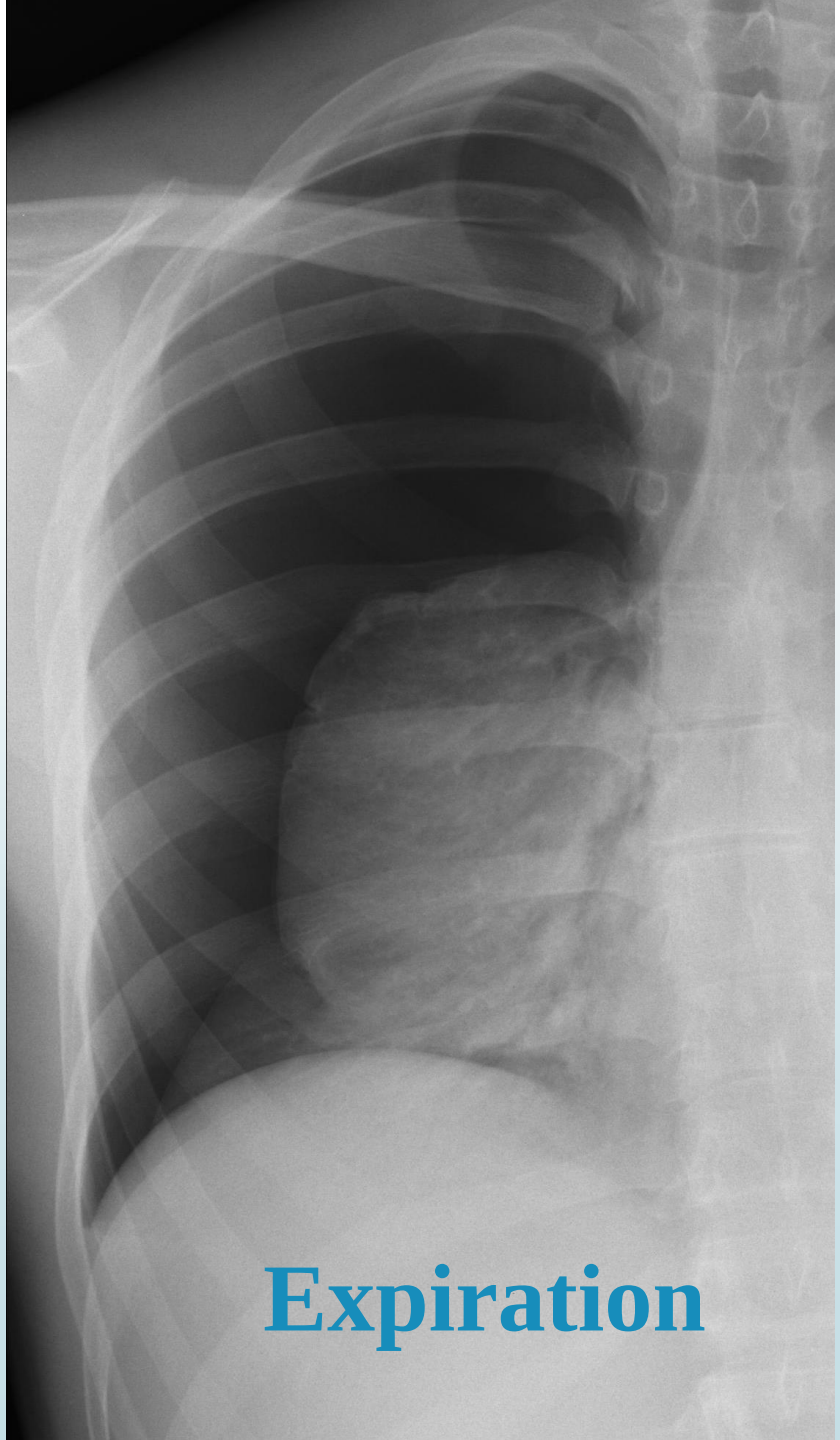
Expiration

Tension Pneumothorax

- No vascular markings on right
- Shift of mediastinum to left
- Atelectatic right lung
- Increased haziness on left

Tension Pneumothorax

This chest film shows the potentially fatal condition of a tension pneumothorox.

In inspiration, the right lung is completely collapsed but the media- stinum is central.

In expiration, air is trapped in the right hemithorox under positive pressure and the heart and left lung are compressed to the left.

Cardiac venous return is obstructed with potentially fatal results if the pleural cavity is not urgently drained.

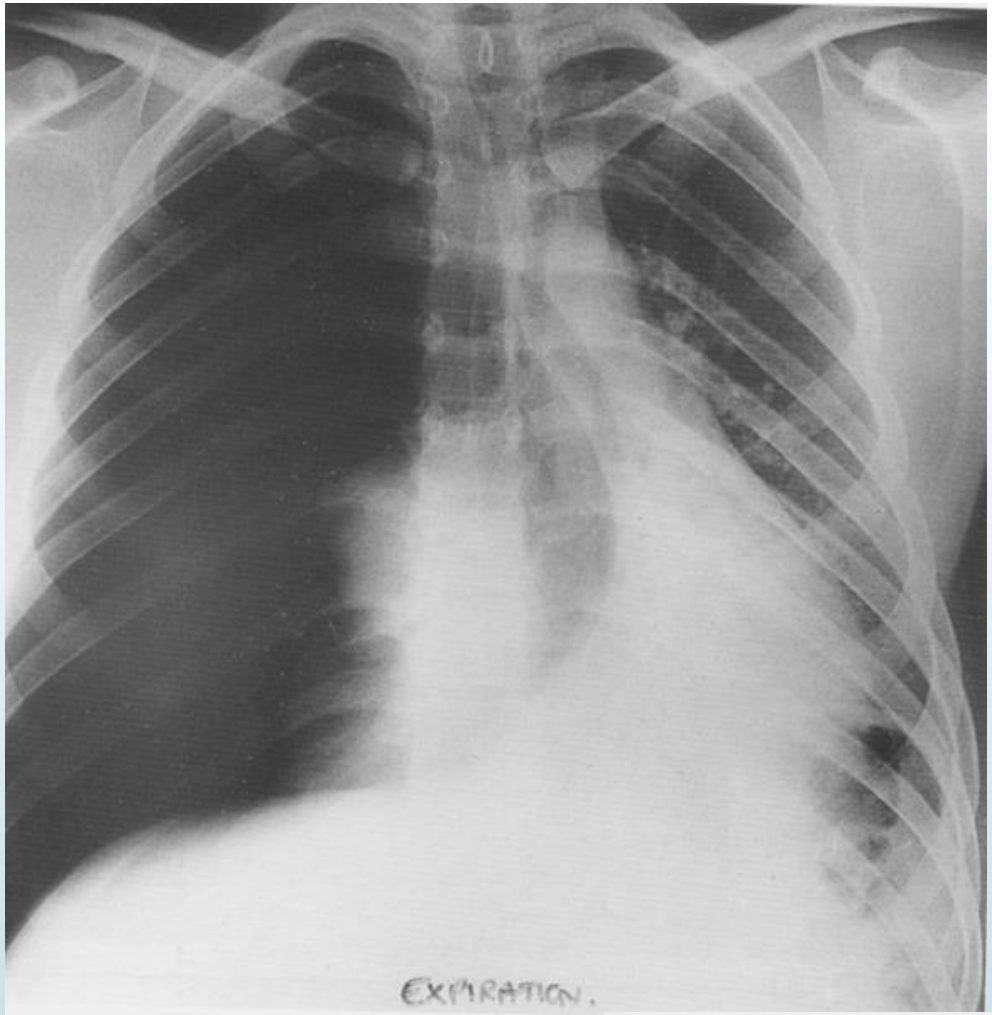

Tension Pneumothorax

- This film shows a right sided tension pneumothorax with right sided lucency and leftward mediastinal shift. This is a medical emergency.
- Failure to place a right chest tube immediately could allow venous return to diminish and lead to possible death.

Tension Pneumothorax

Tension Pneumothorax

Right Sided tension pneumothorax

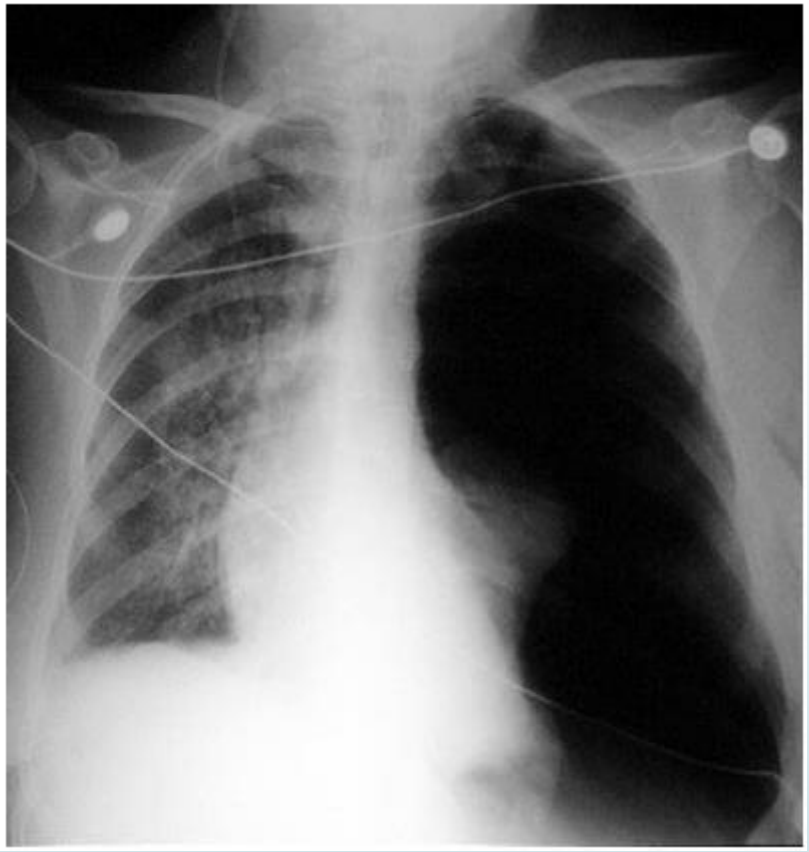

Left Sided tension pneumothorax

Hydropneumothorax

- Hydropneumothorax : implies presence of both air and fluid in the pleural space (i.e. between two layers of pleura. An erect chest x-ray will show the air fluid level. The horizontal fluid level is usually well defined and extends across the whole length of hemithorax.

- Signs of hydropneumothorax can be remembered by 4 'S'
  - Straight line dullness
  - Shifting dullness
  - Succussion splash
  - Sound of coin

Hydropneumothorax

- Air in pleural cavity
- Lung margin visible
- Bilateral fluid level: Any time you see a horizontal fluid level, it means that there is air and fluid in the pleural space

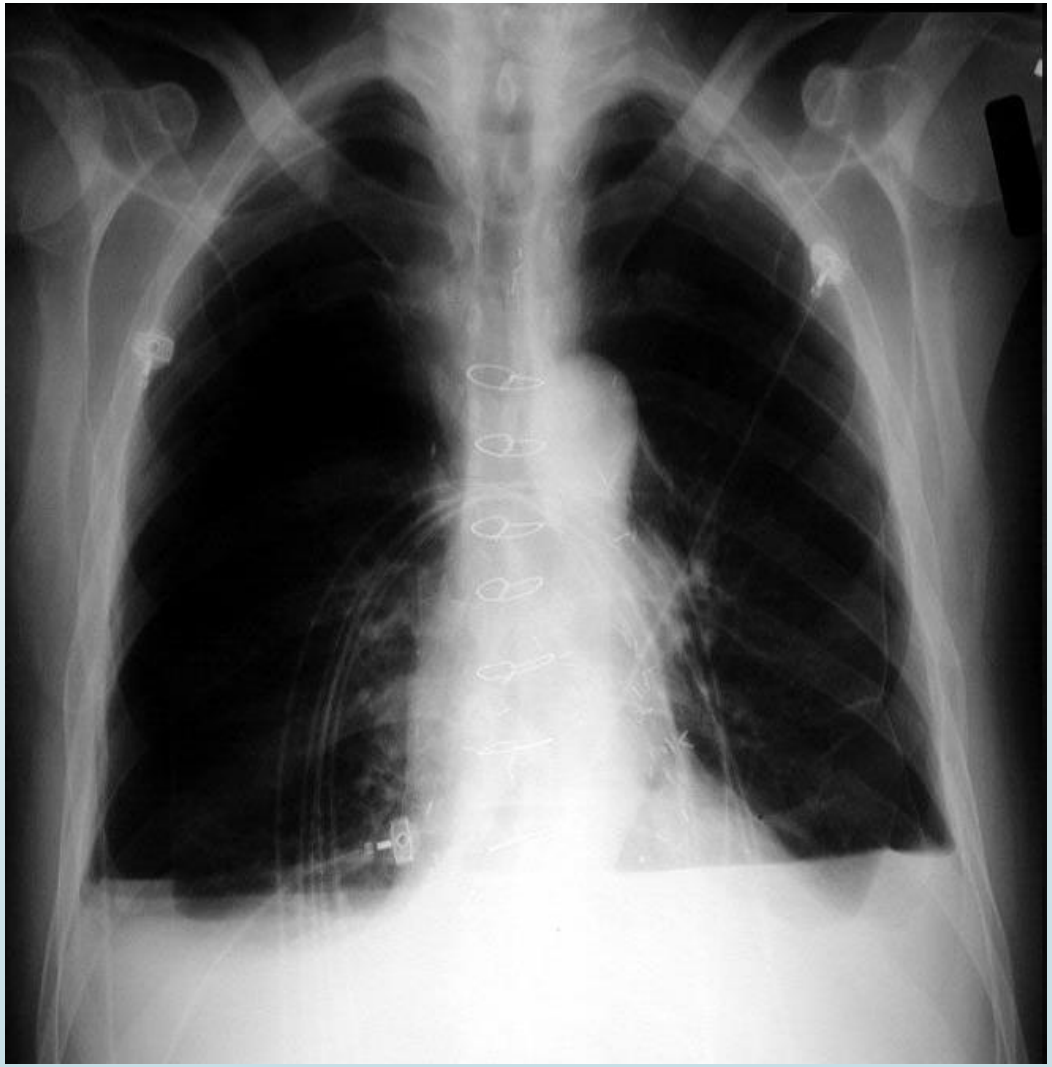


THANK
YOU!